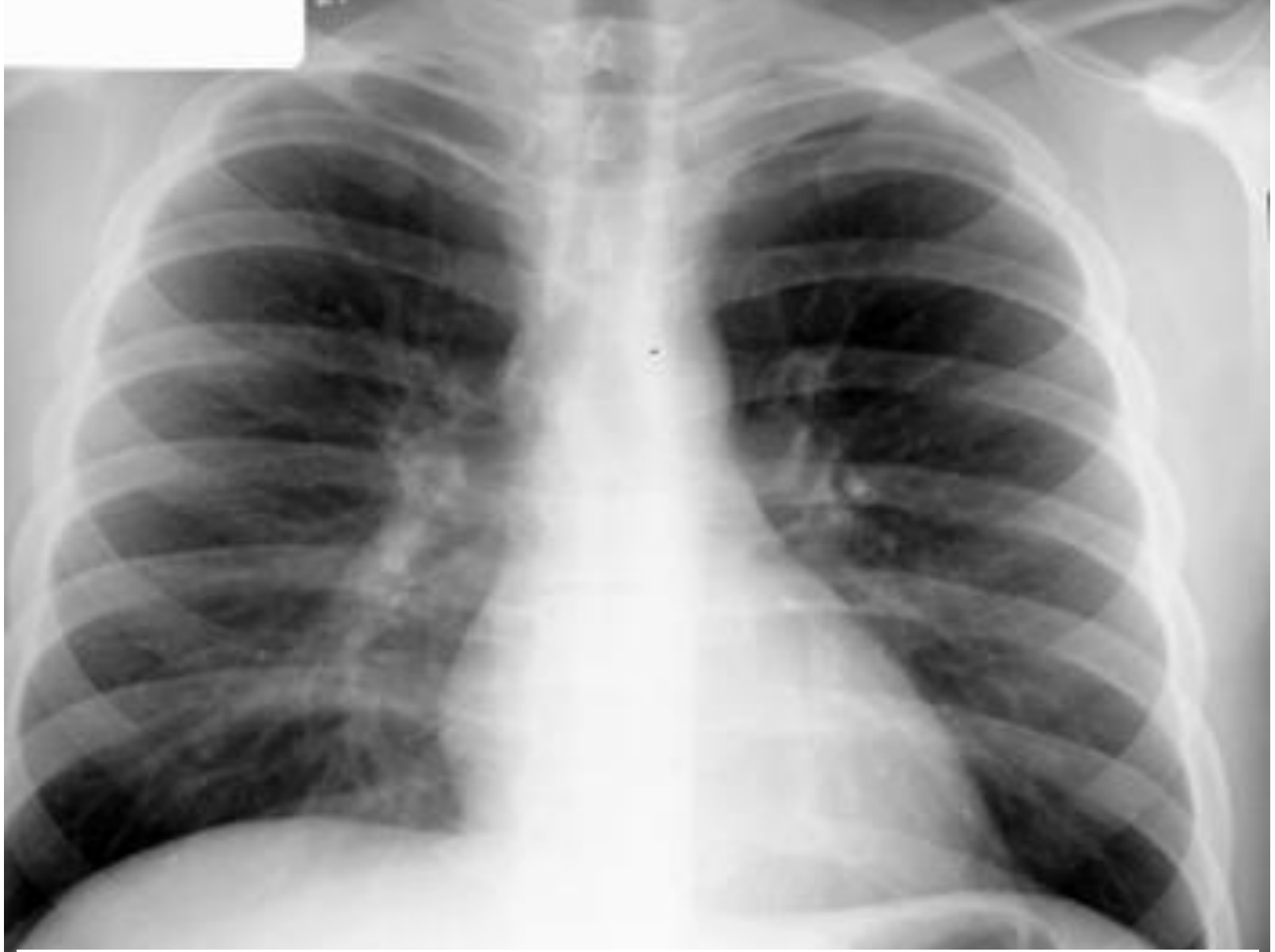

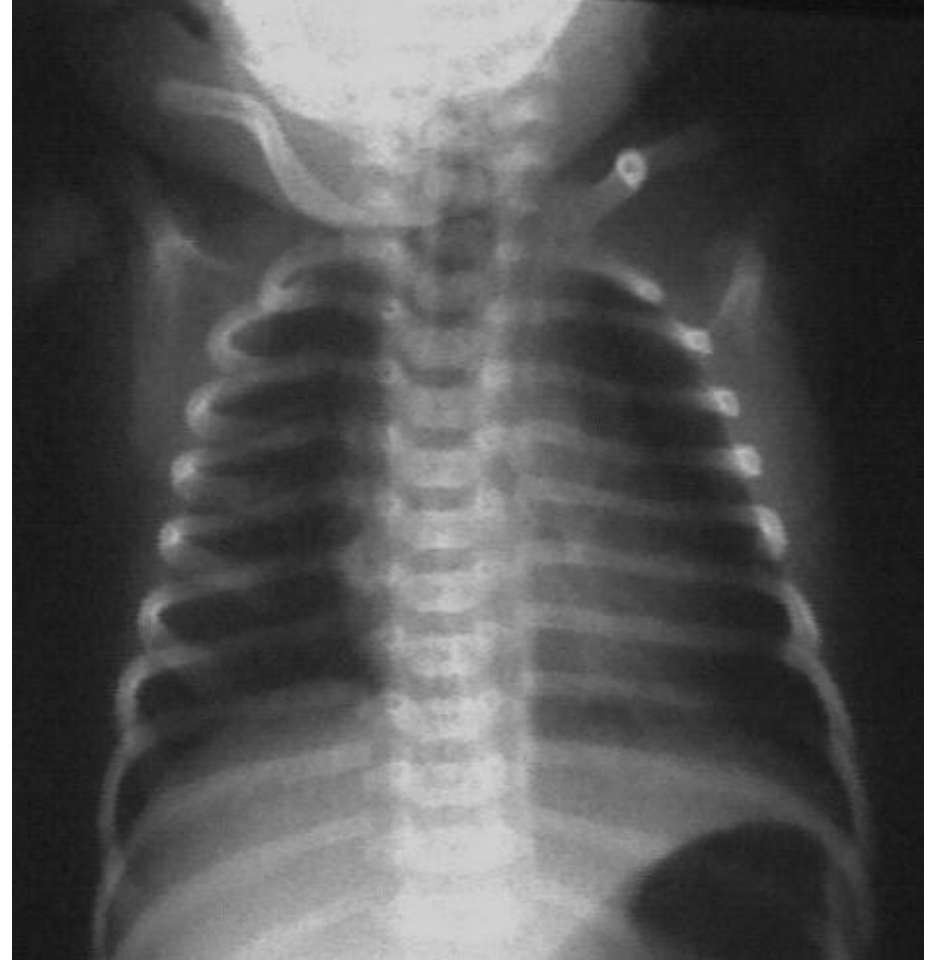
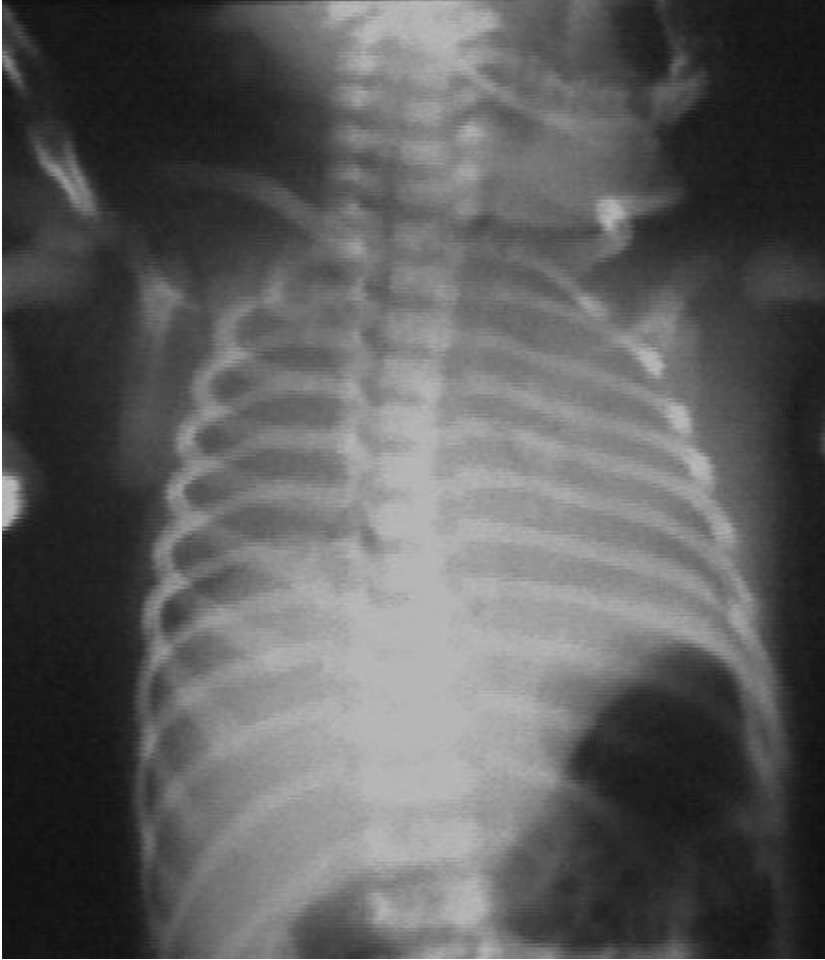ÇOCUK GÖĞÜS HASTALIKLARINDA RADYOLOJİ

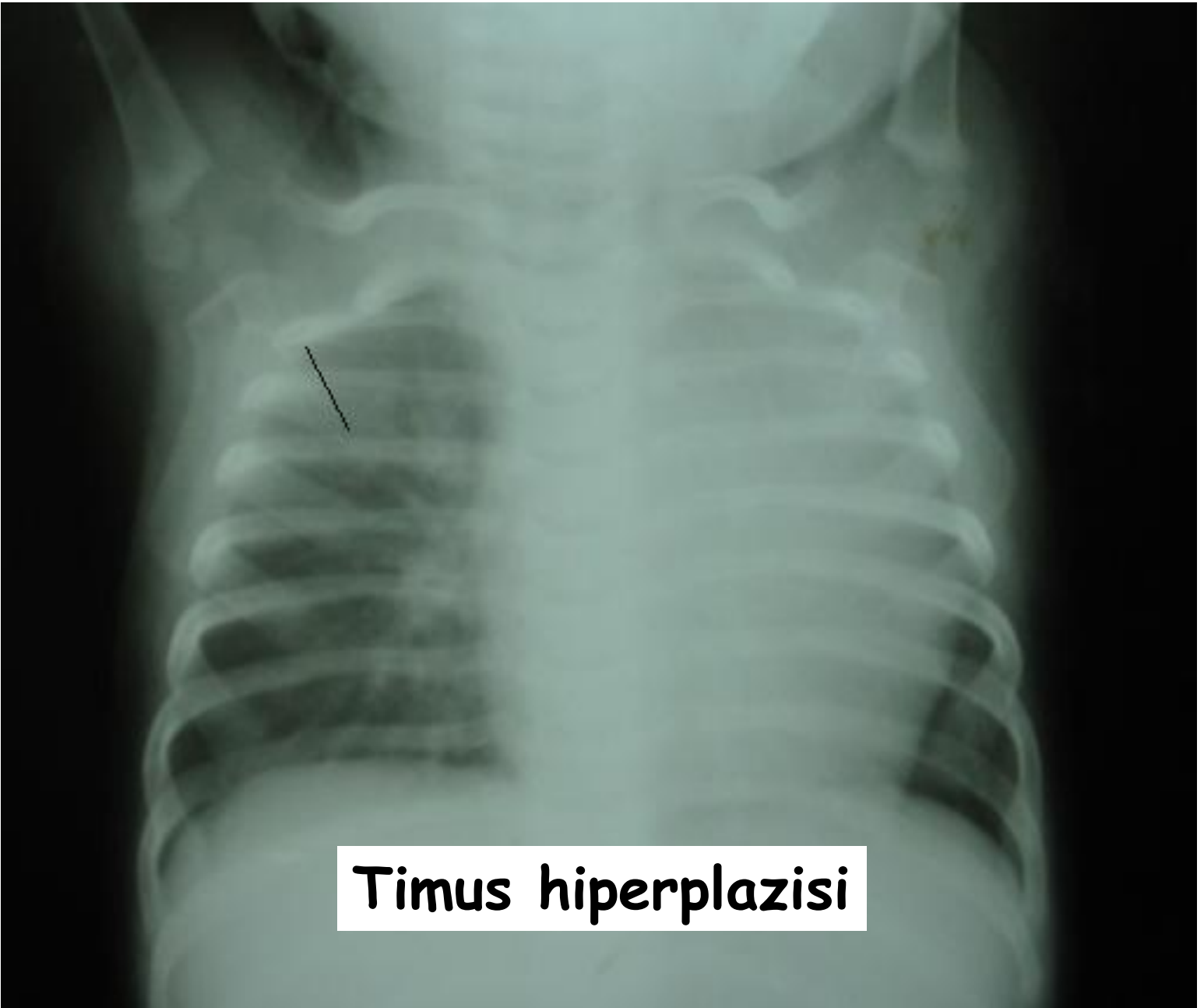
**Dr. Fazilet Karakoç
Marmara Üniversitesi
Çocuk Göğüs Hastalıkları Bilim Dalı**



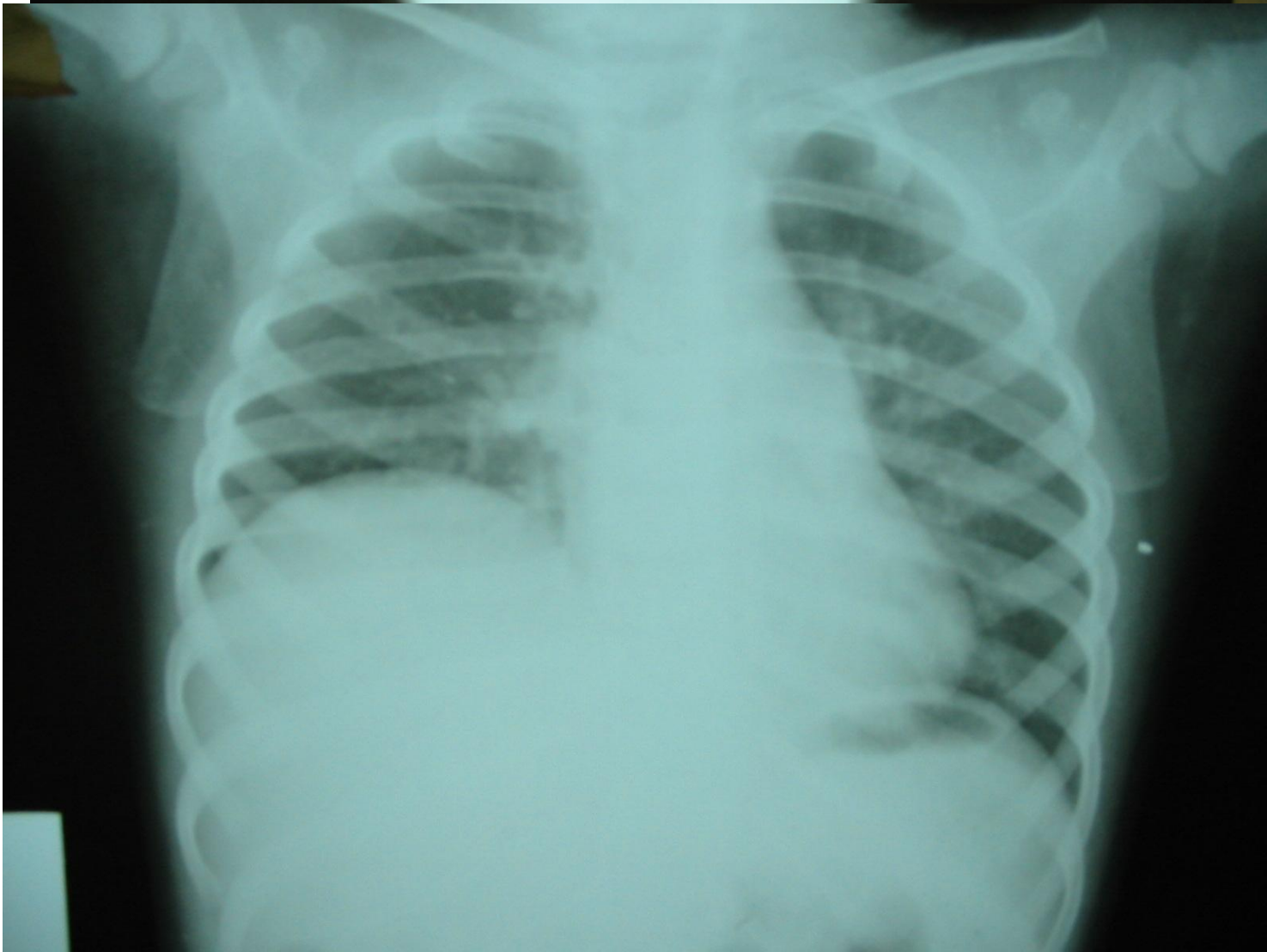
AP ve PA akciğer grafileri arasındaki fark

İnspiryum ve ekspiryum grafileri arasındaki fark

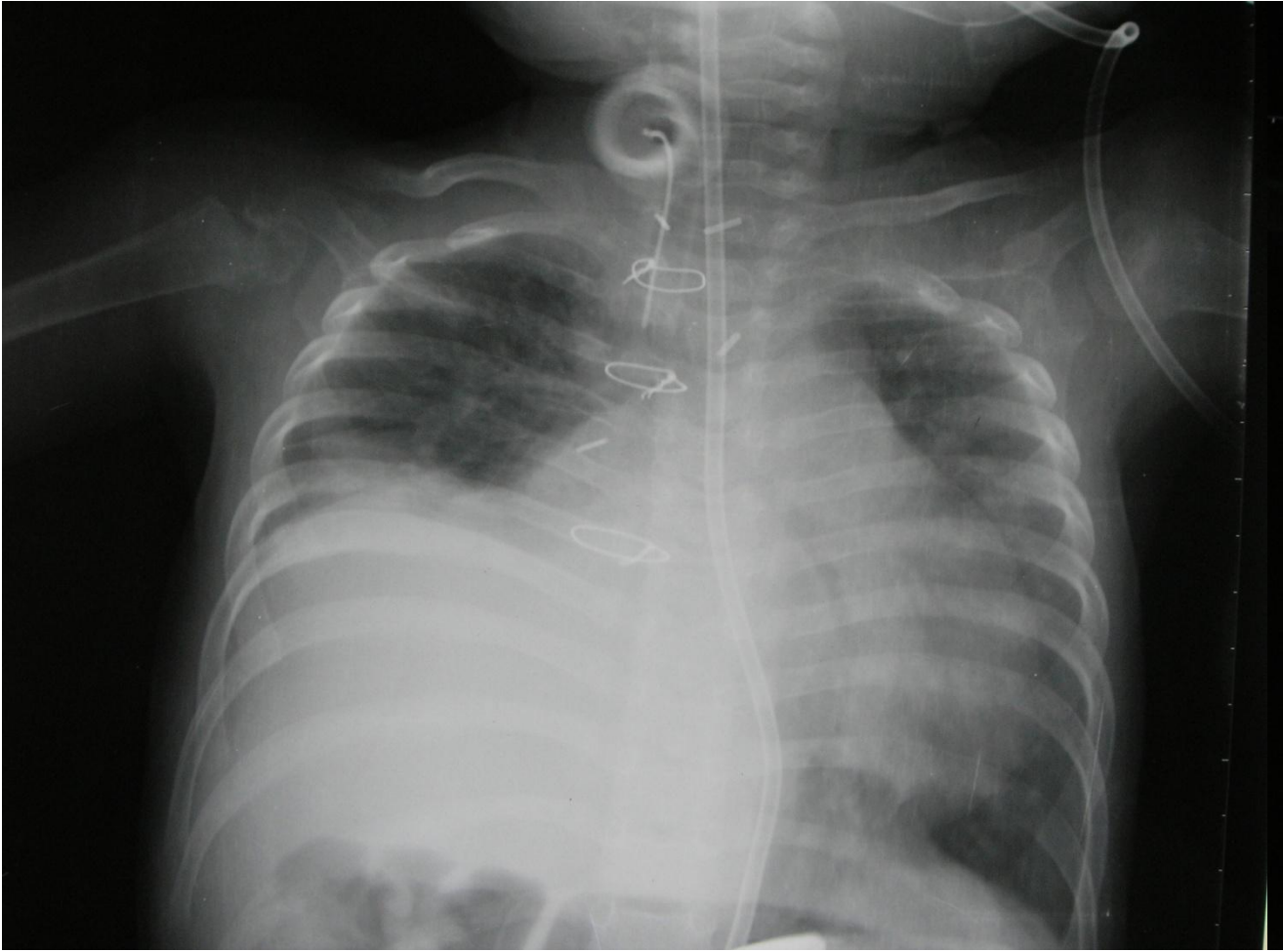




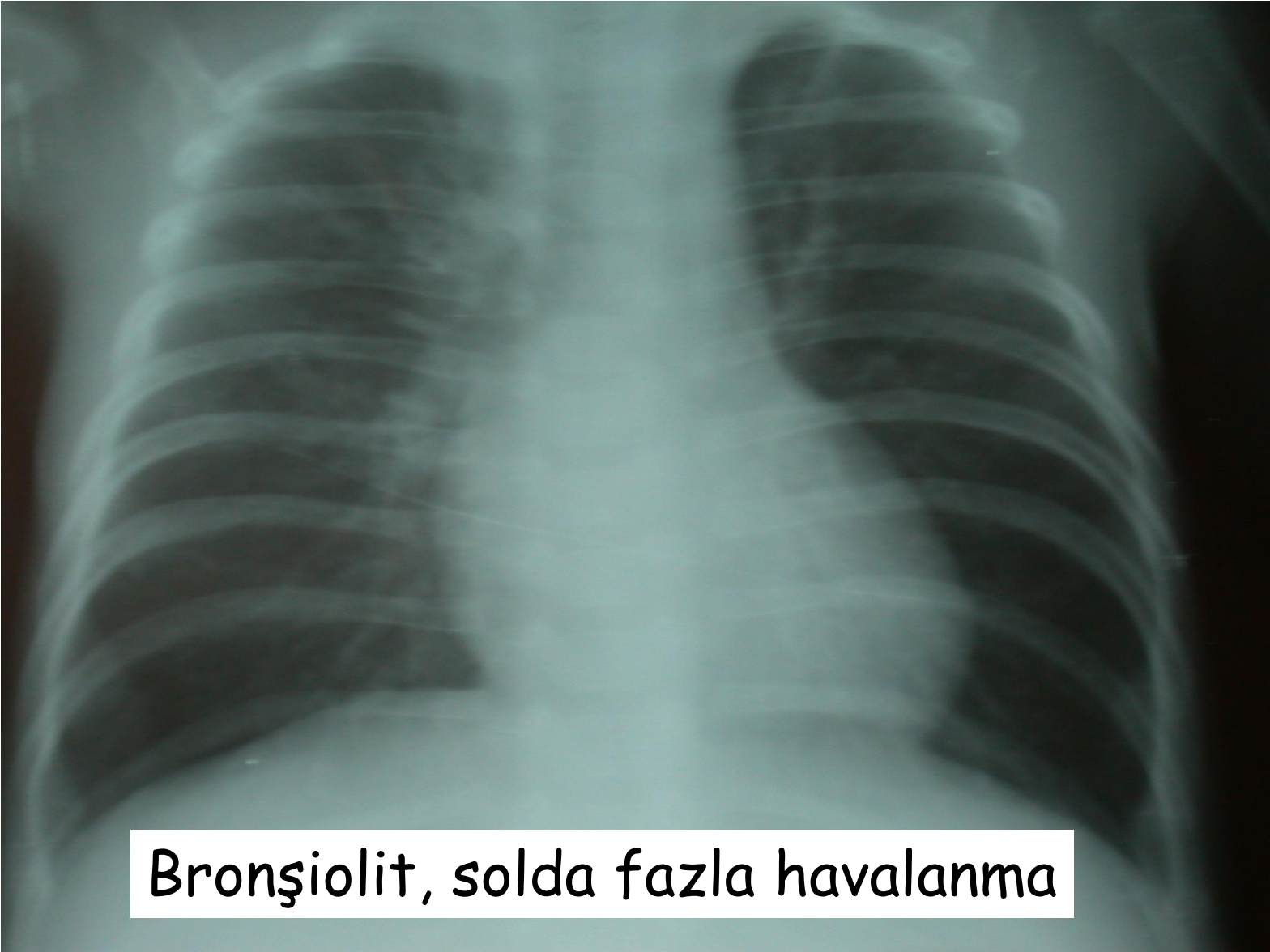
Timus hiperplazisi



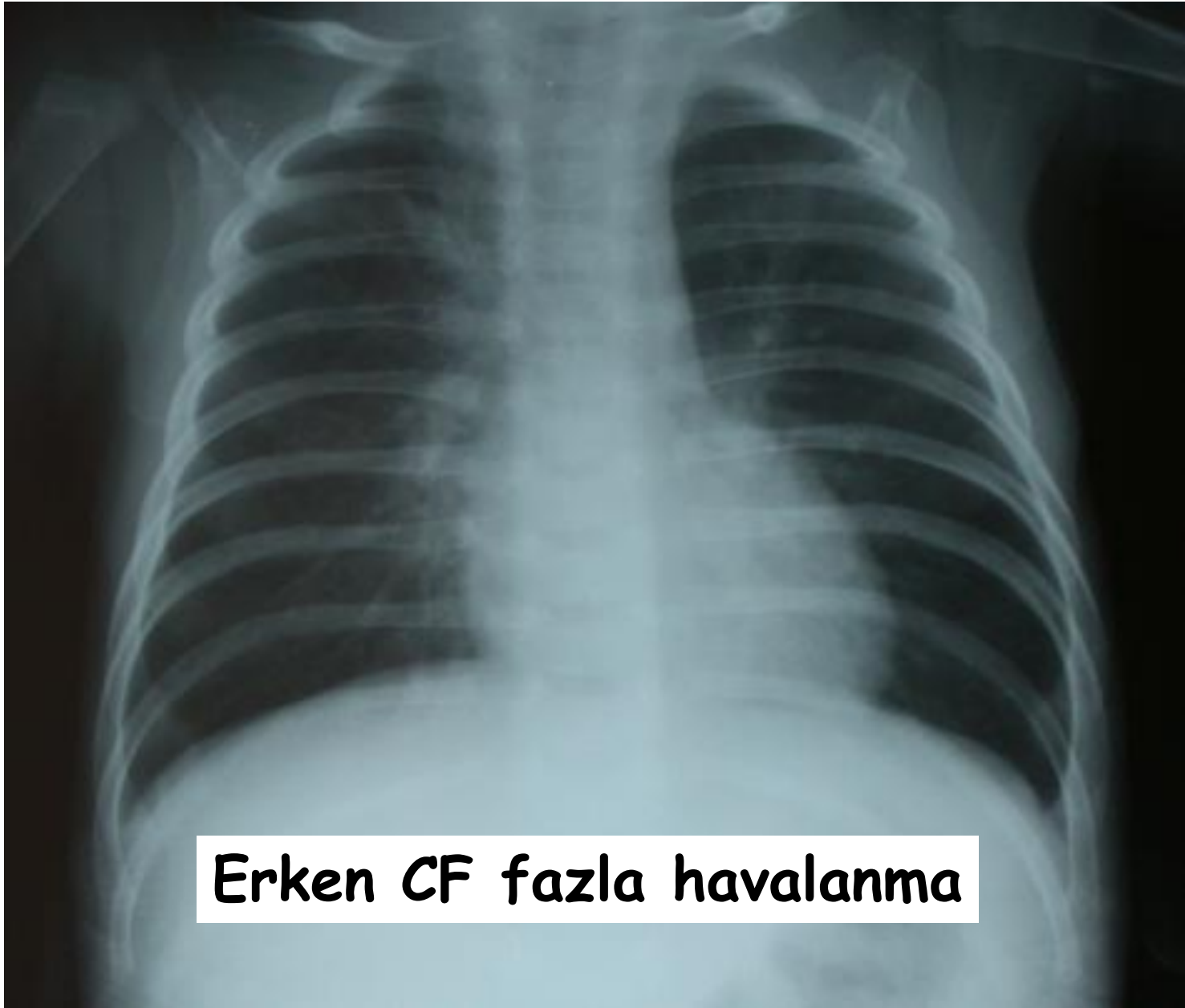Diafram evantrasyonu



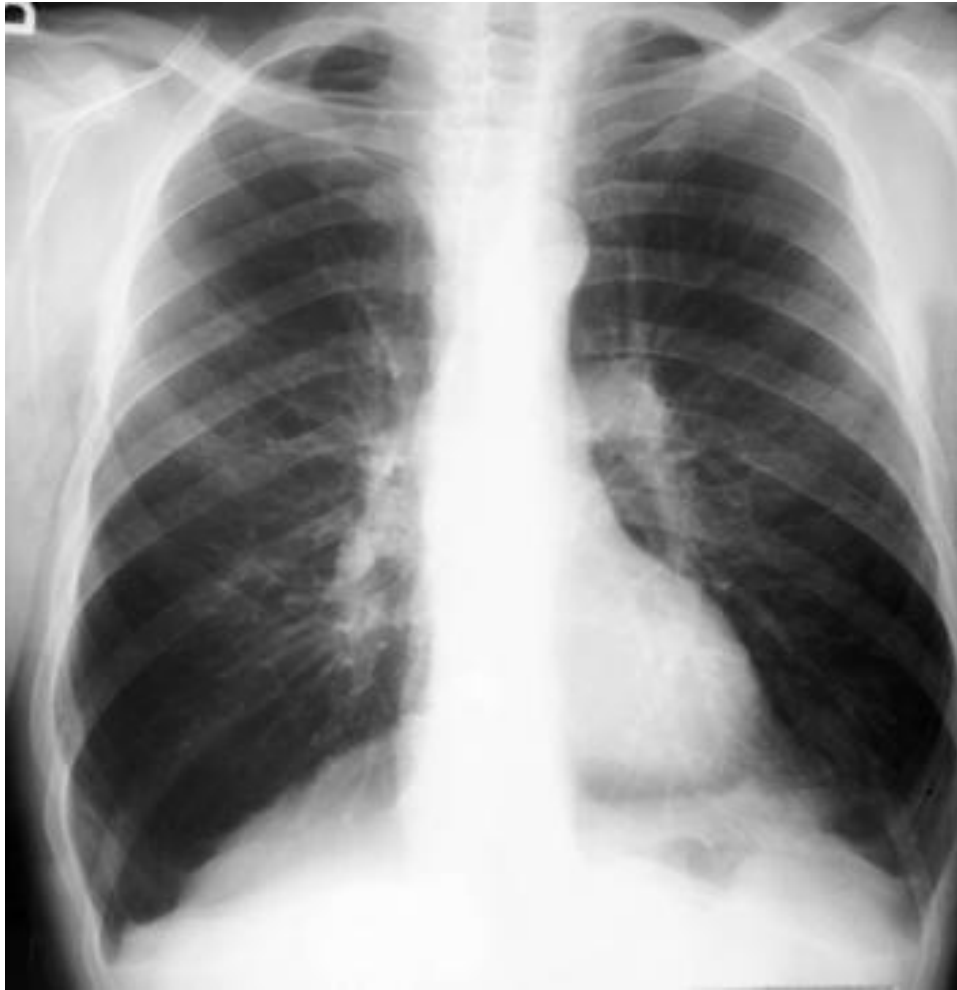Diafragma paralizi tanısı ile Kardiyak operasyondan 4 ay 10 gün sonra plikasyon yapıldı, trakeostomi çıkarıldı fakat oksijen ihtiyacı ve atelektazileri nedeni ile iki yıl süre ile nazal BIPAP aldı.



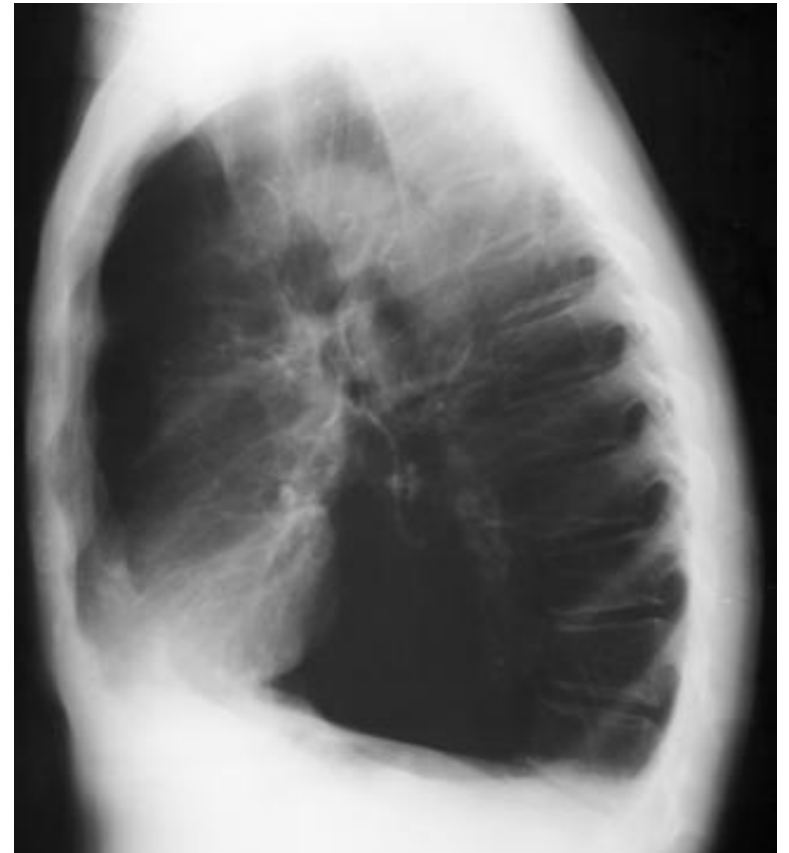Bronşiolit, solda fazla havalanma

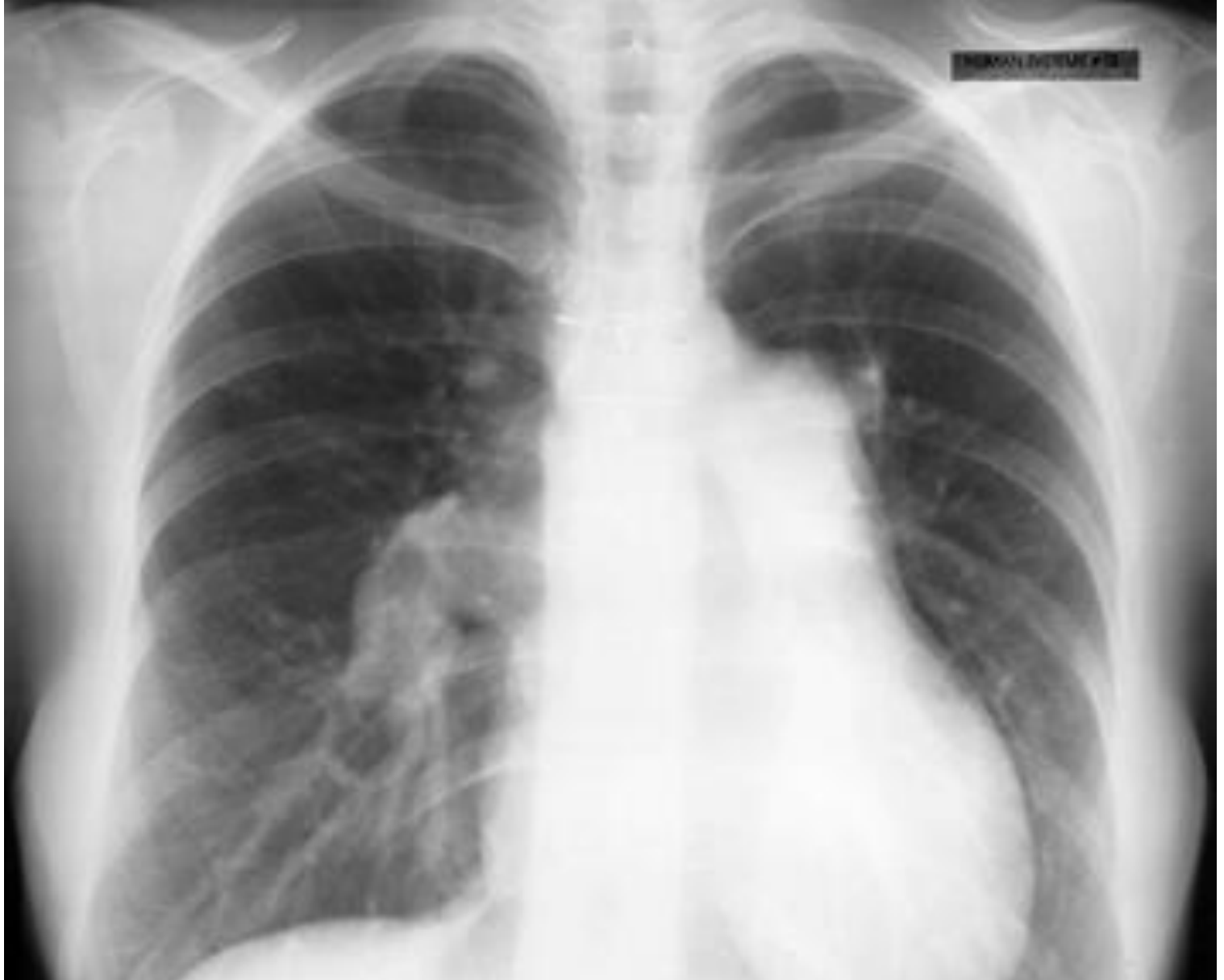

Erken CF fazla havalanma

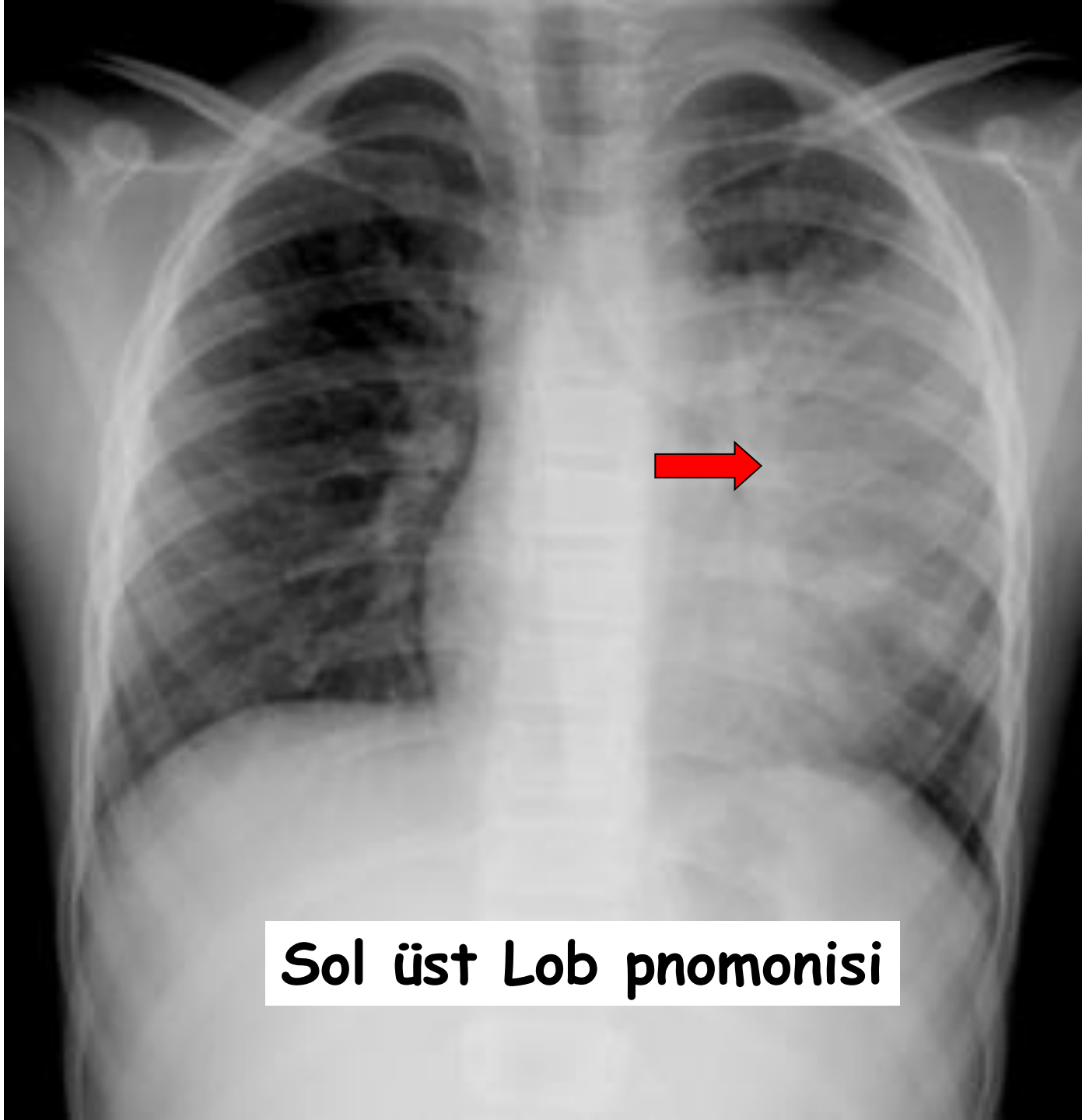


Amfizem

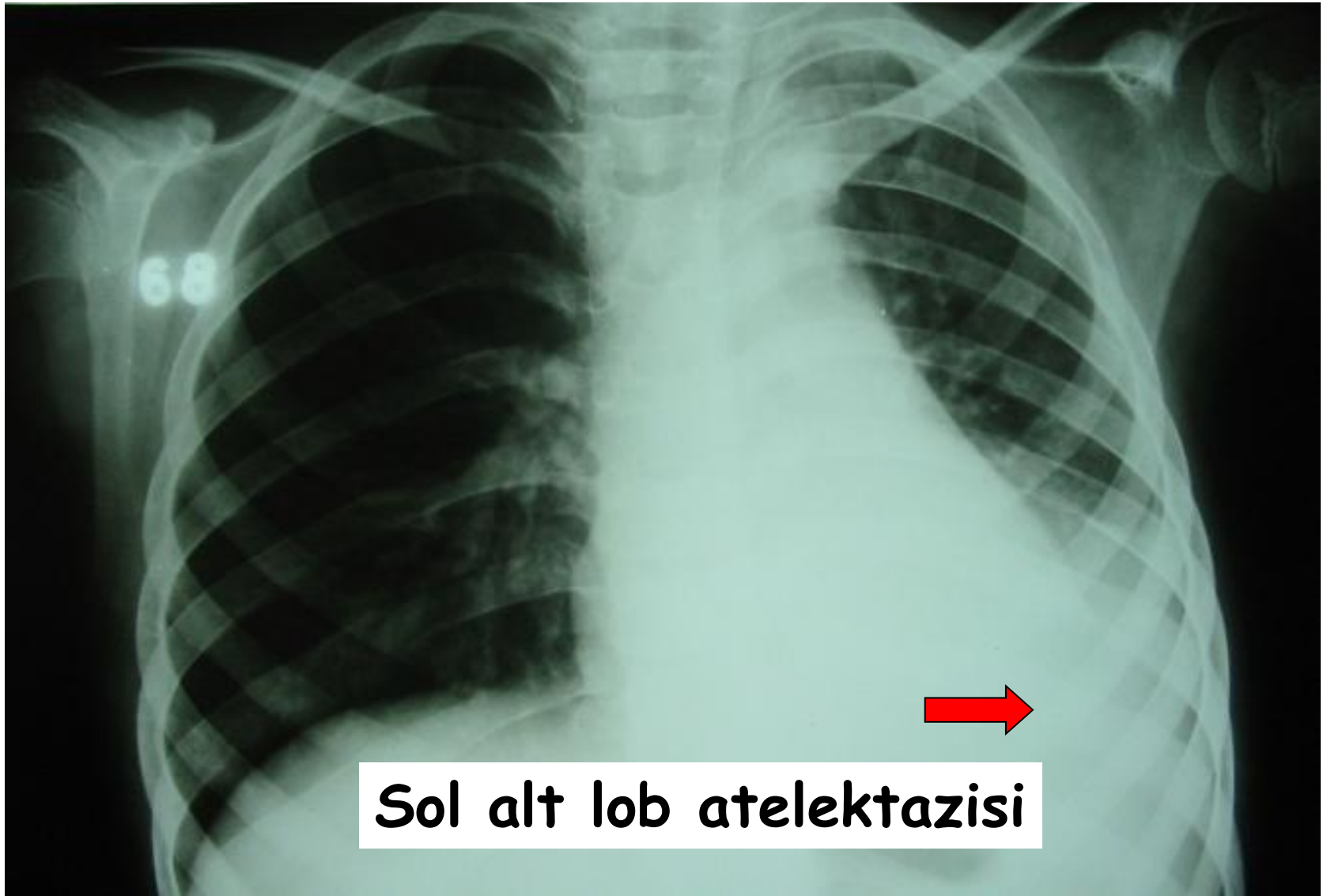



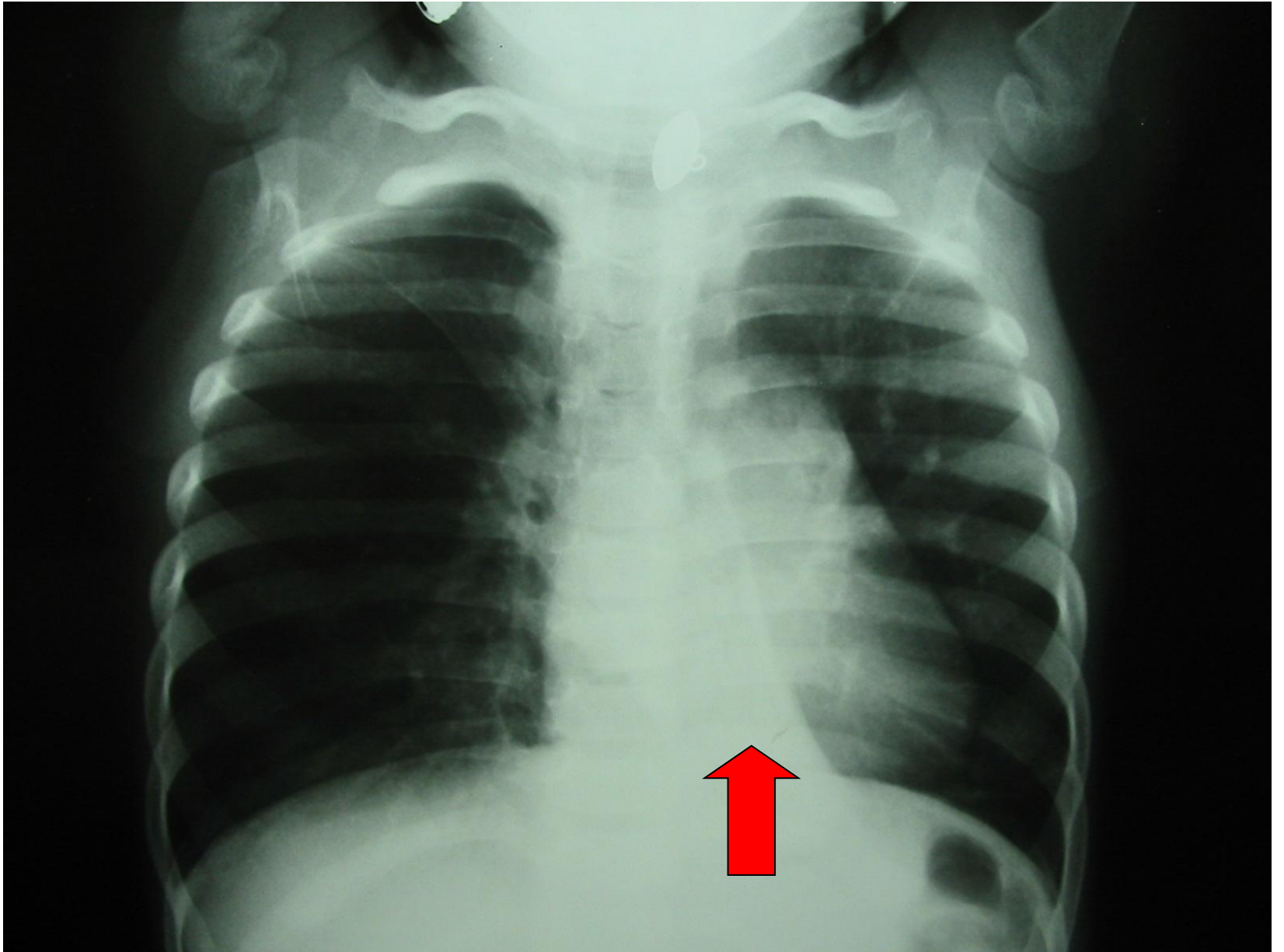
**VSD nedeni ile artmış pulmoner vaskülarite,
geniş pulmoner arterler**

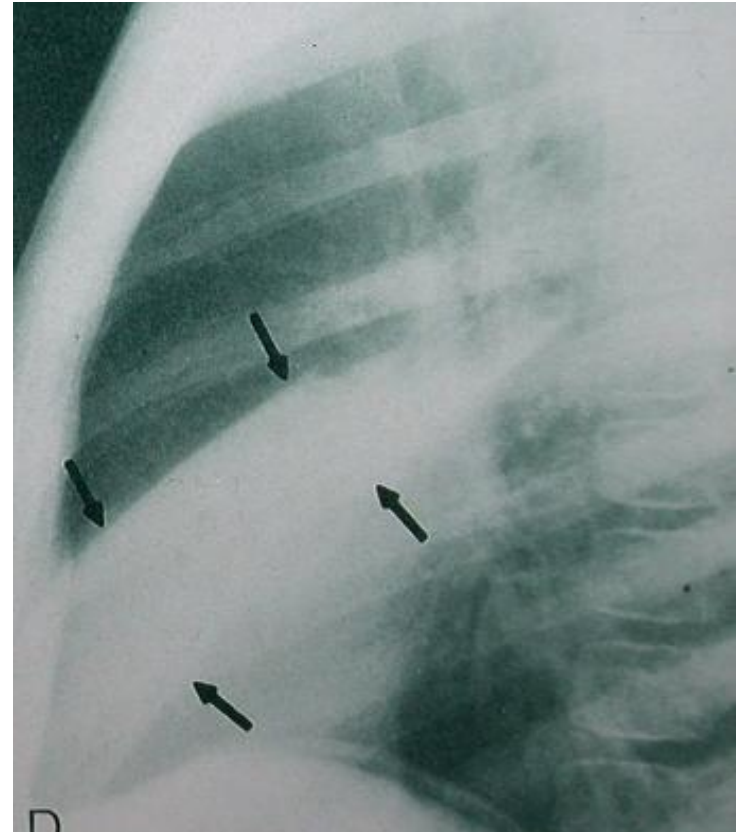
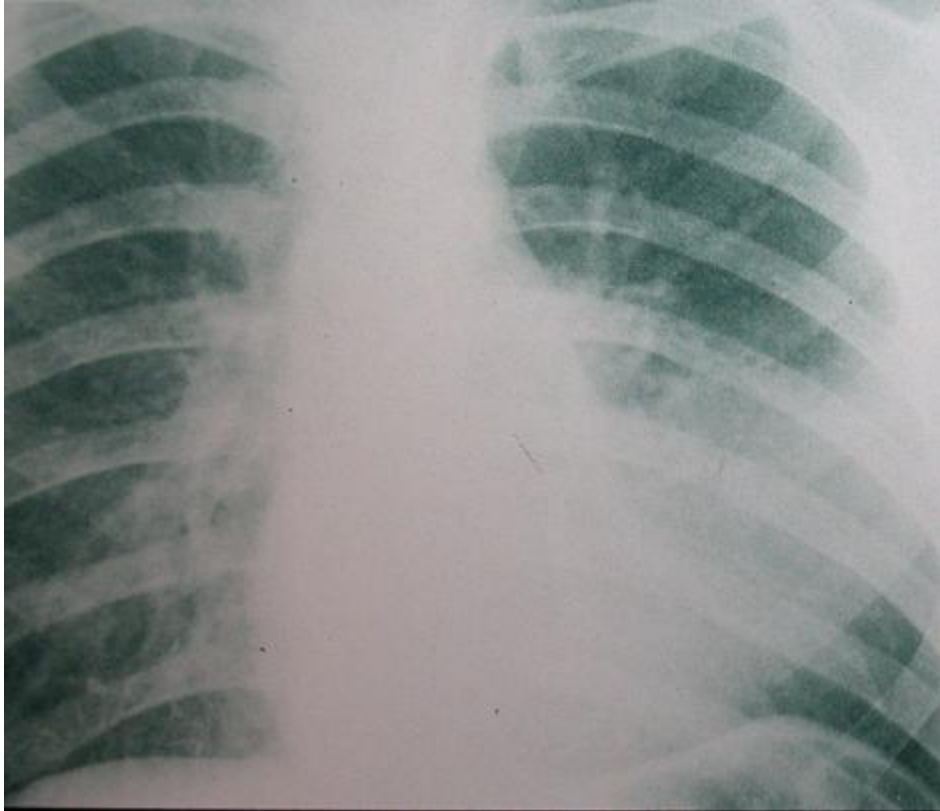


Sol üst Lob pnomonisi

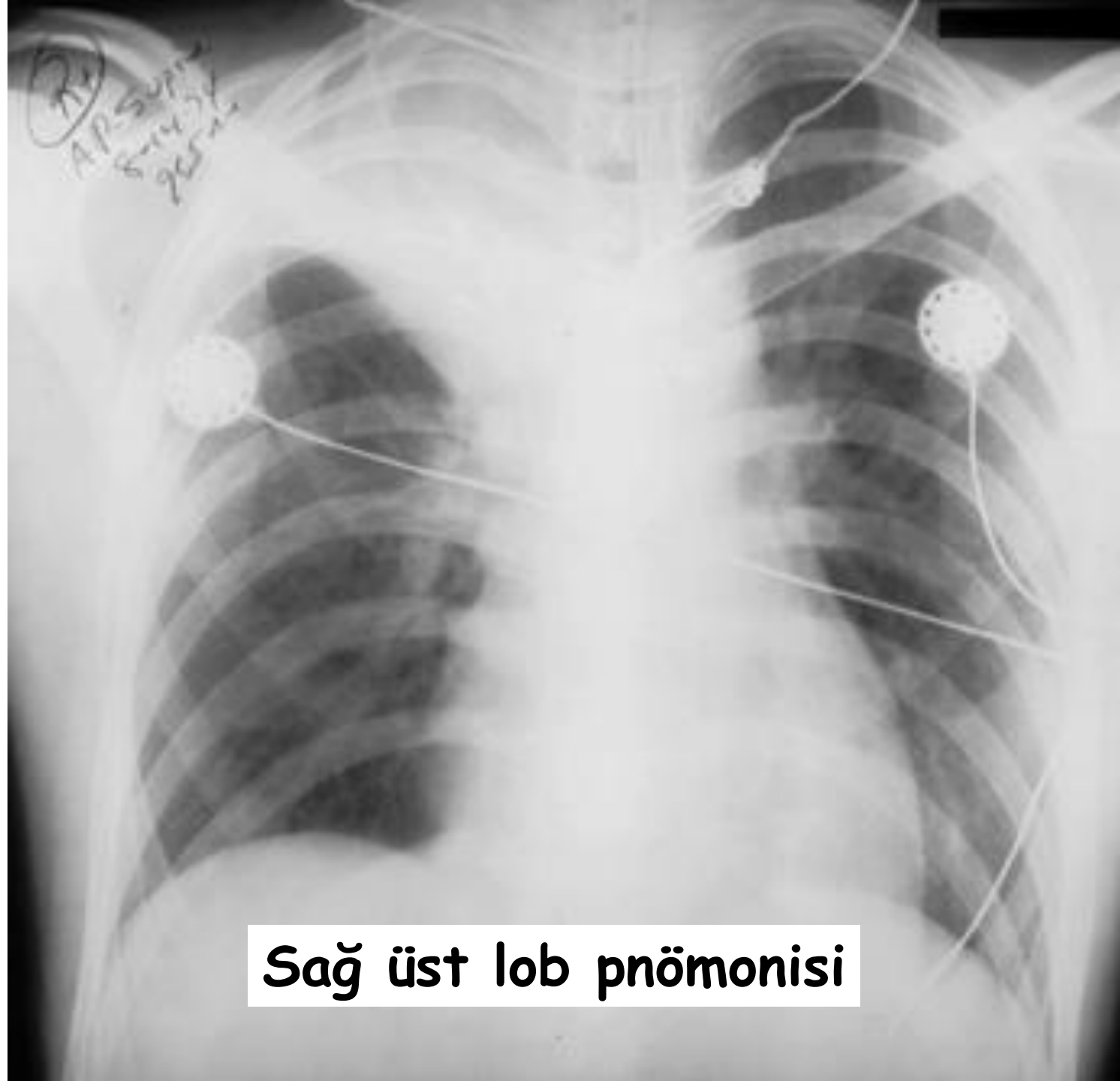

Sol alt lob atelektazisi

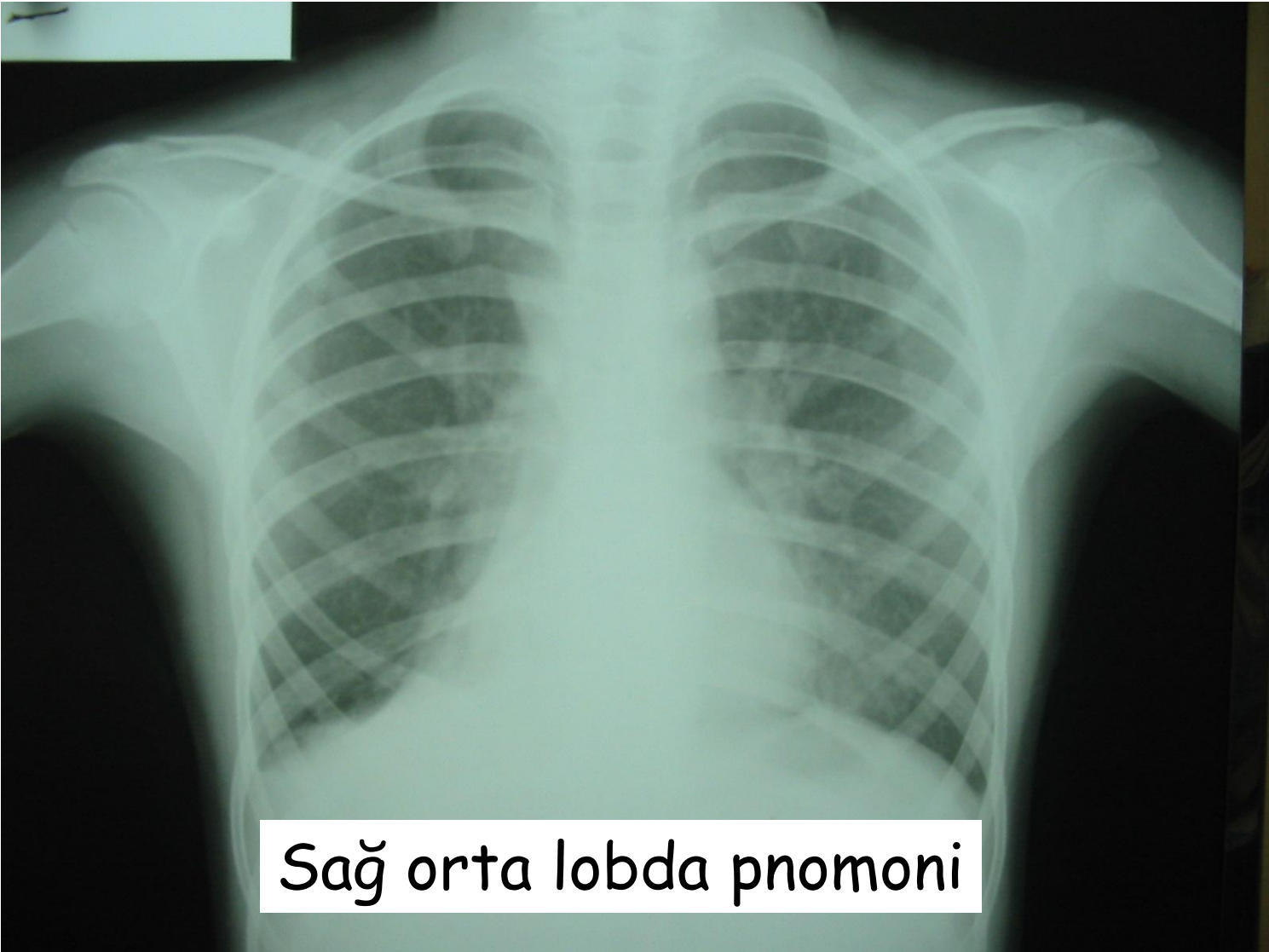



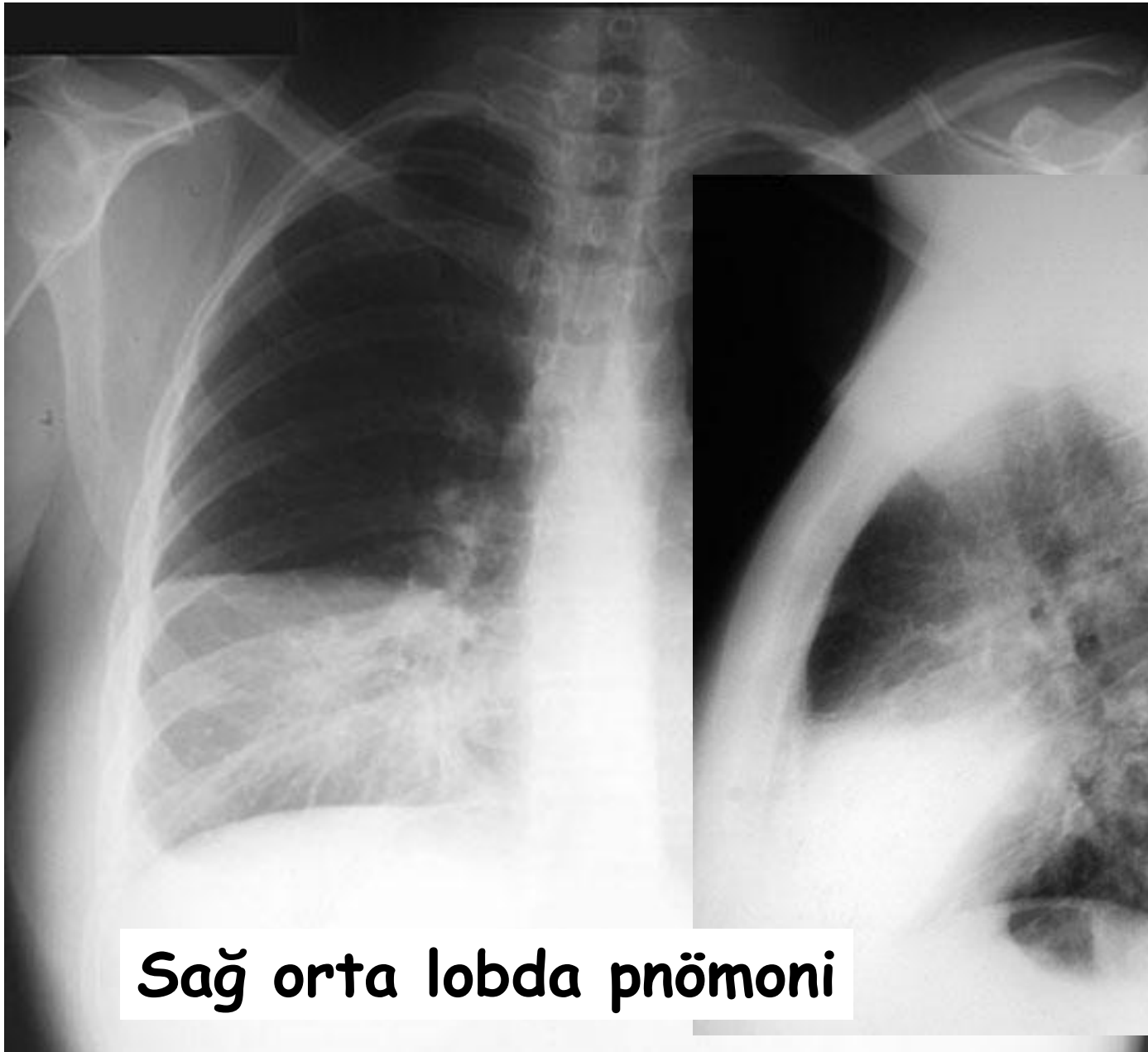Lingulada pnomoni



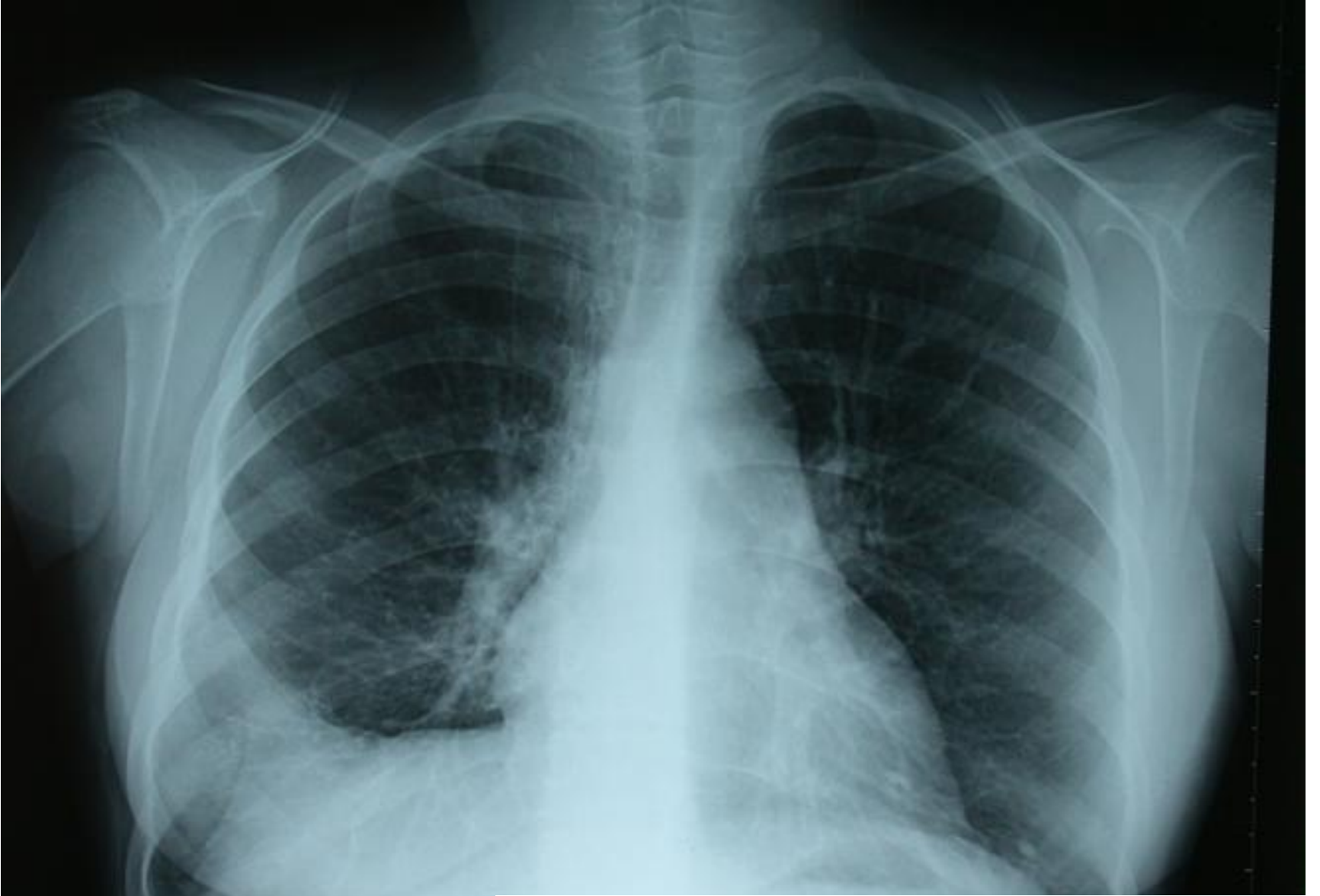
Sağ üst lob pnömonisi



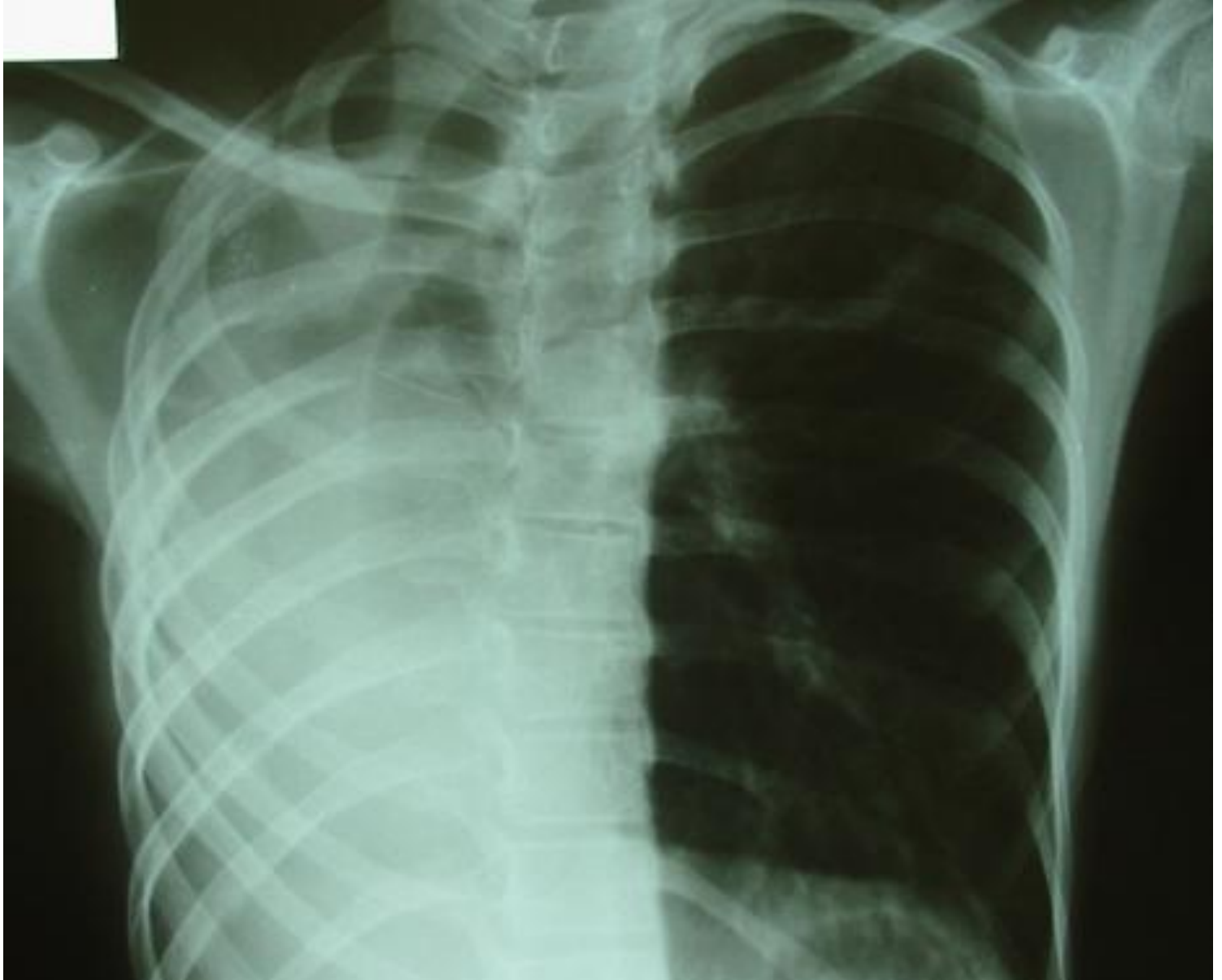Sağ orta lobda pnomoni



Sağ orta lobda pnömoni

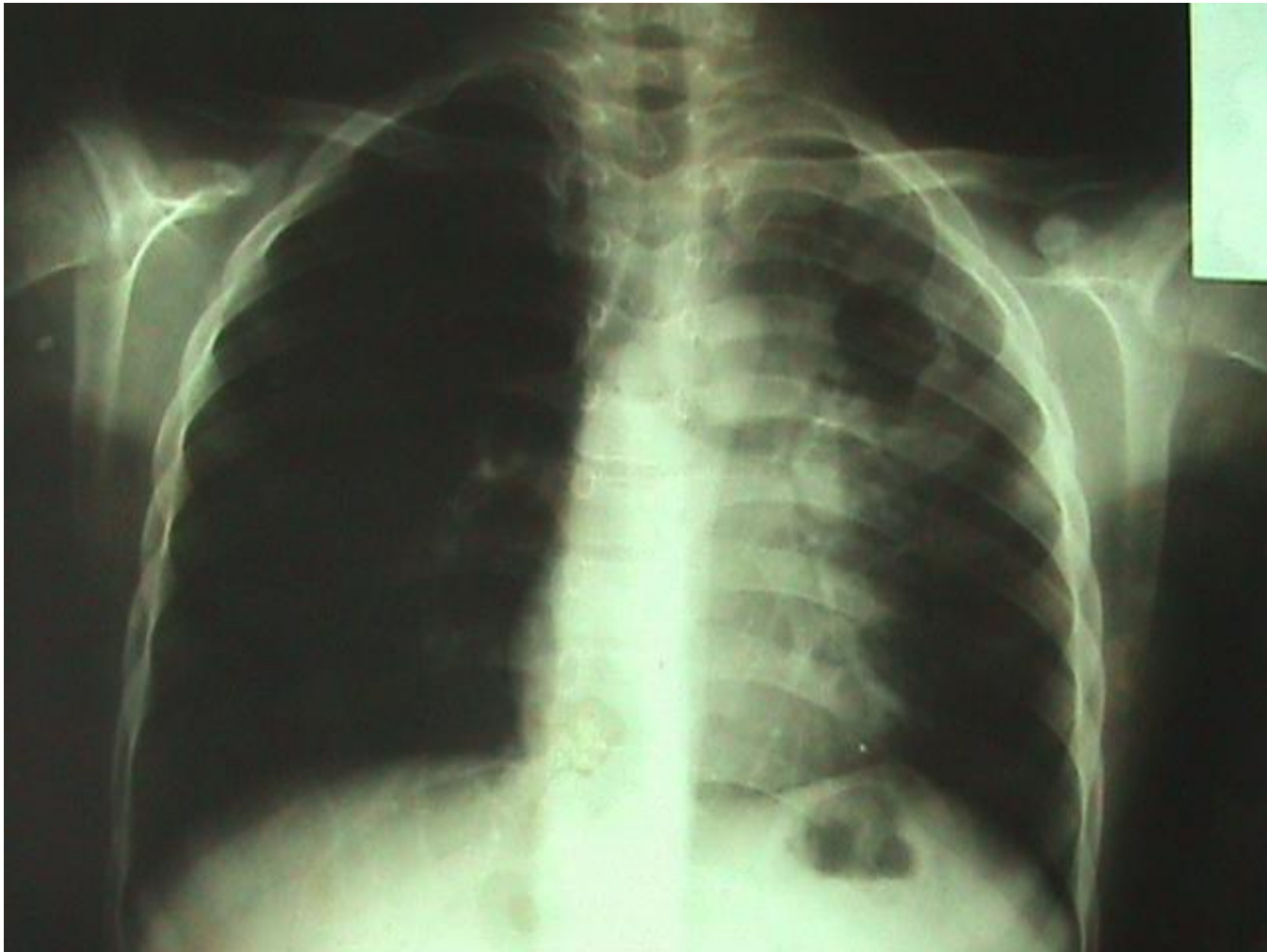

ÖK 18 yaş kız hasta
immun yetmezlik sağ alt lob pnömonisi

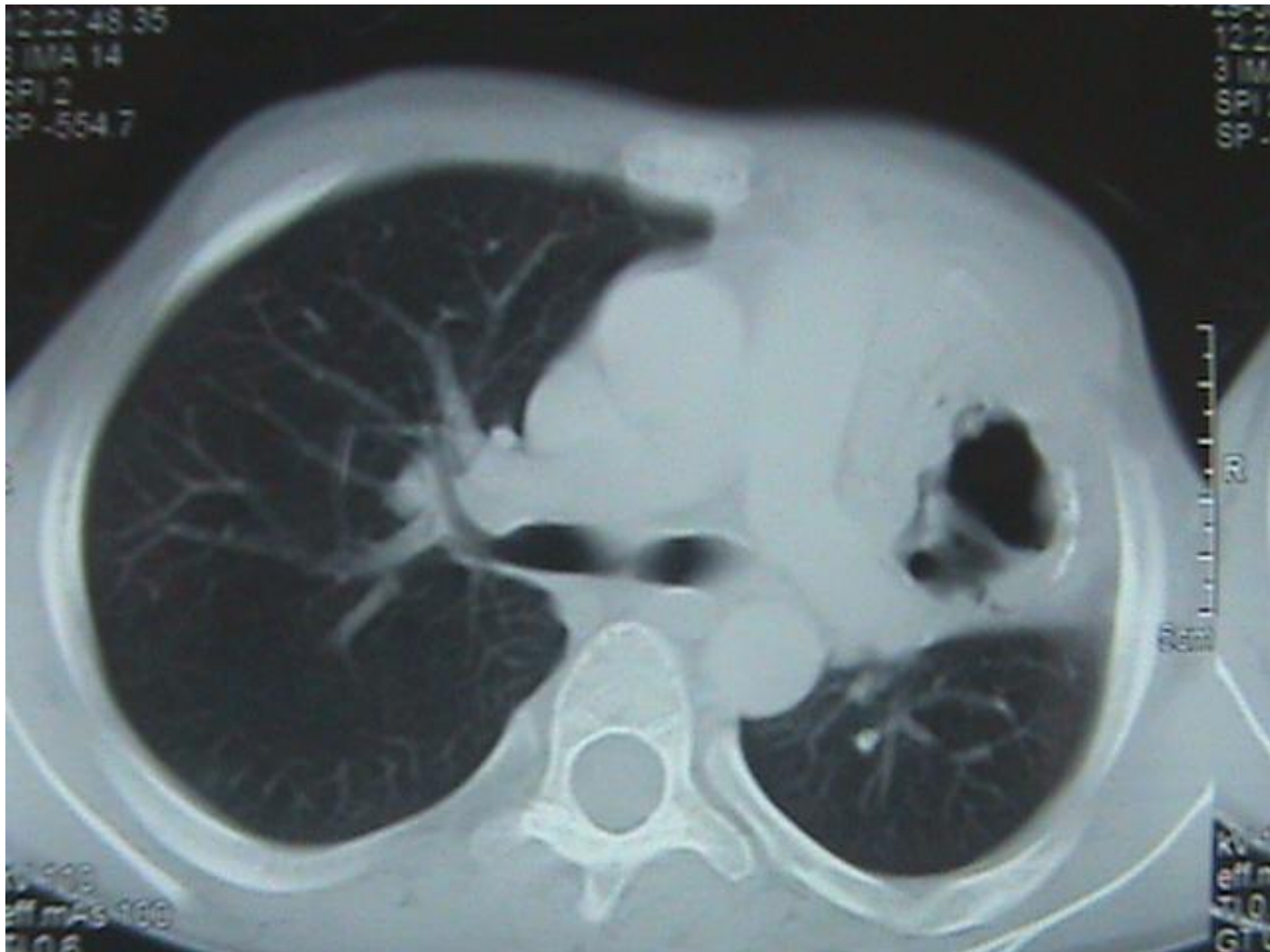


Stafilokok pnomonisi sađda harap olmuş akciđer

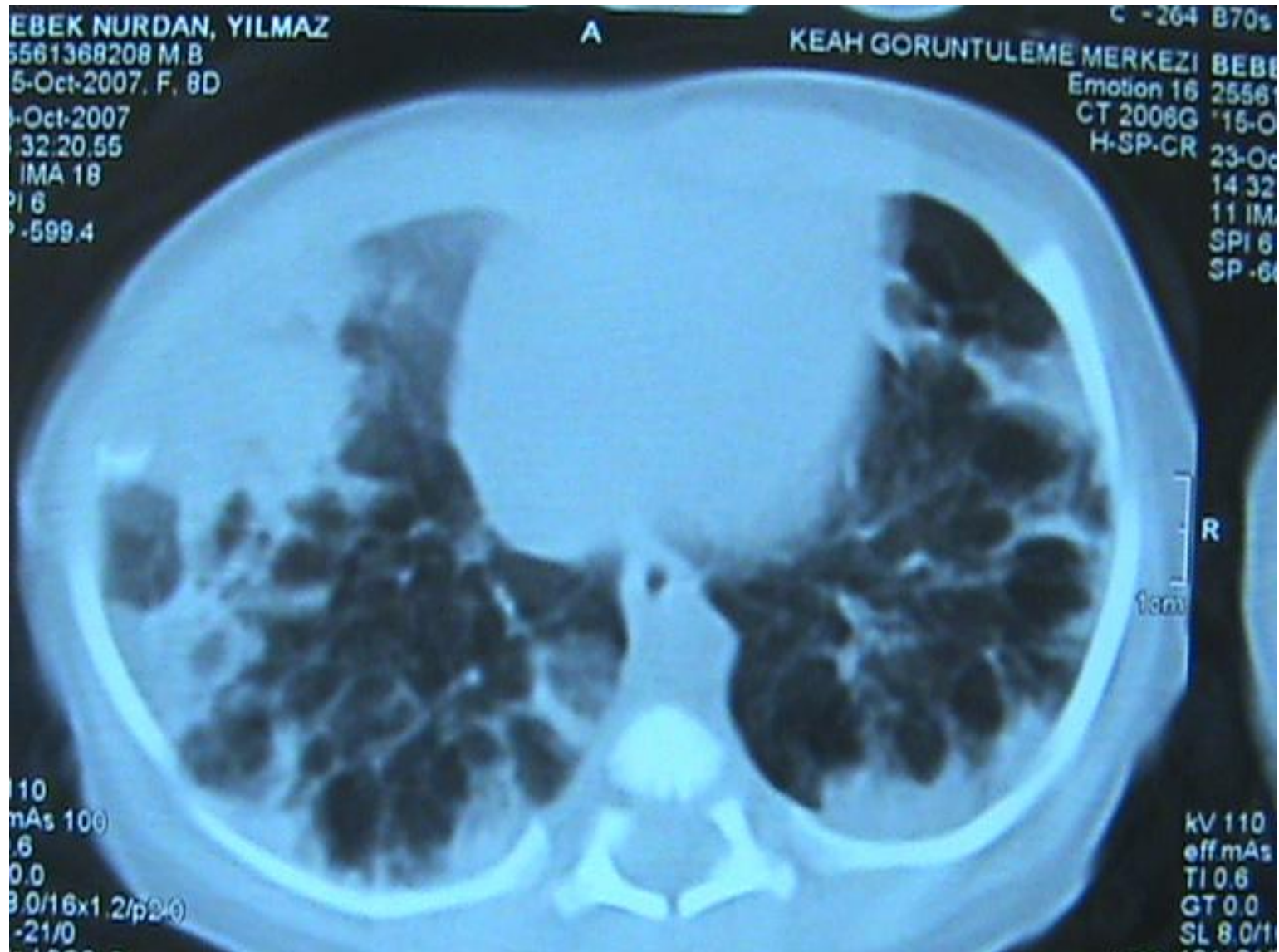
Nekrotizan pnömoni



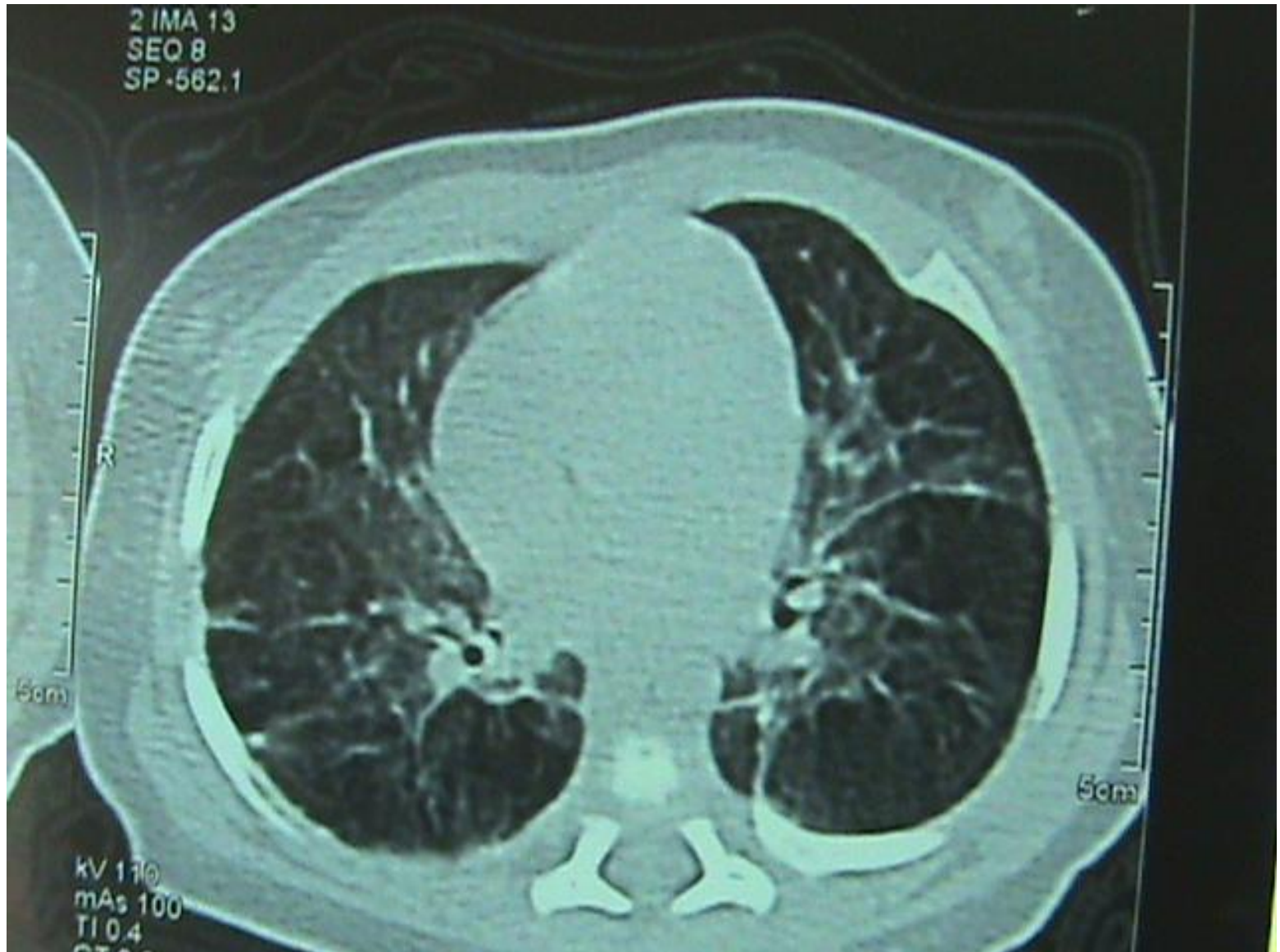
Nekrotizan pnömoni BT

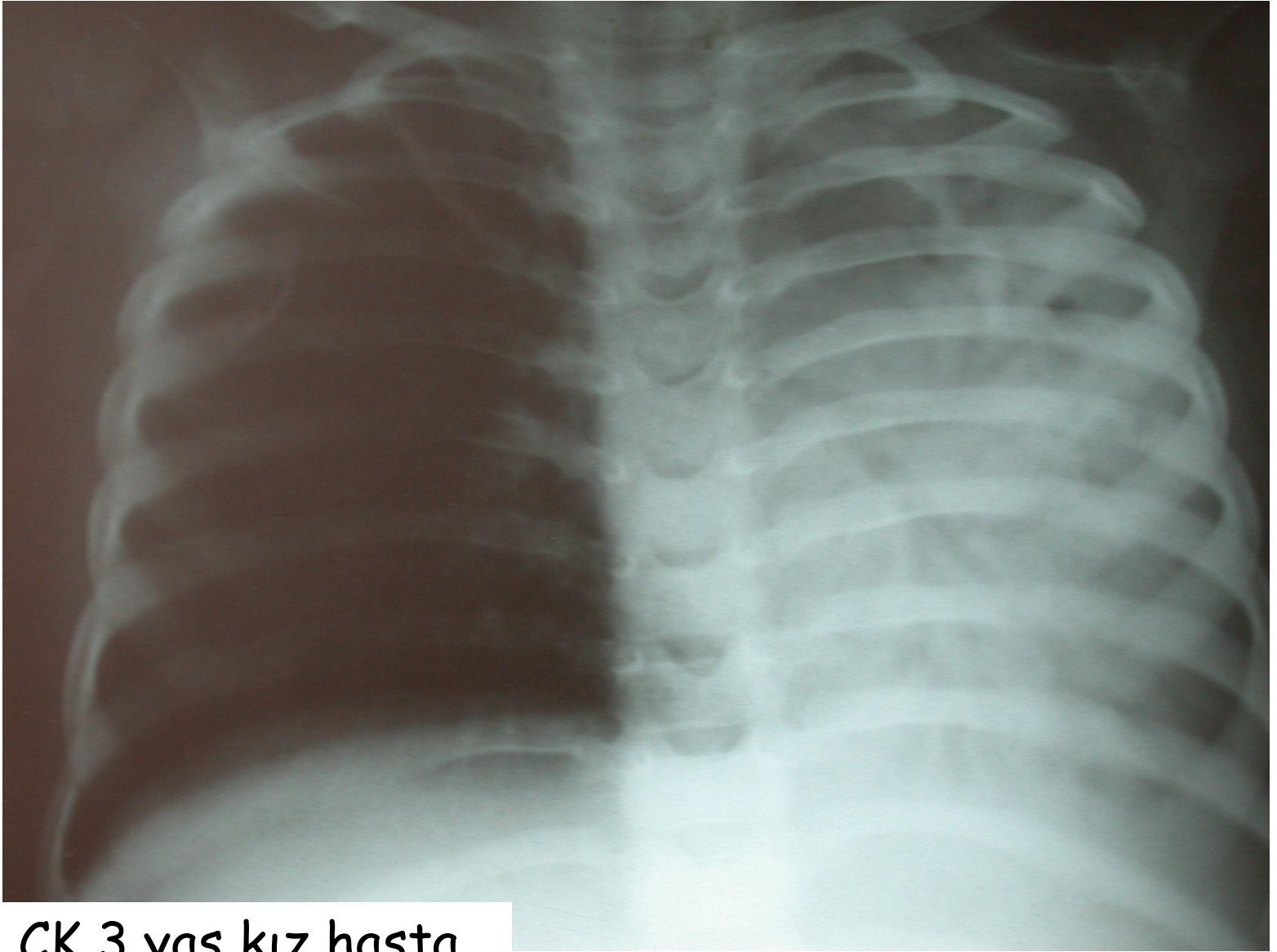


Konjenital pnömoni

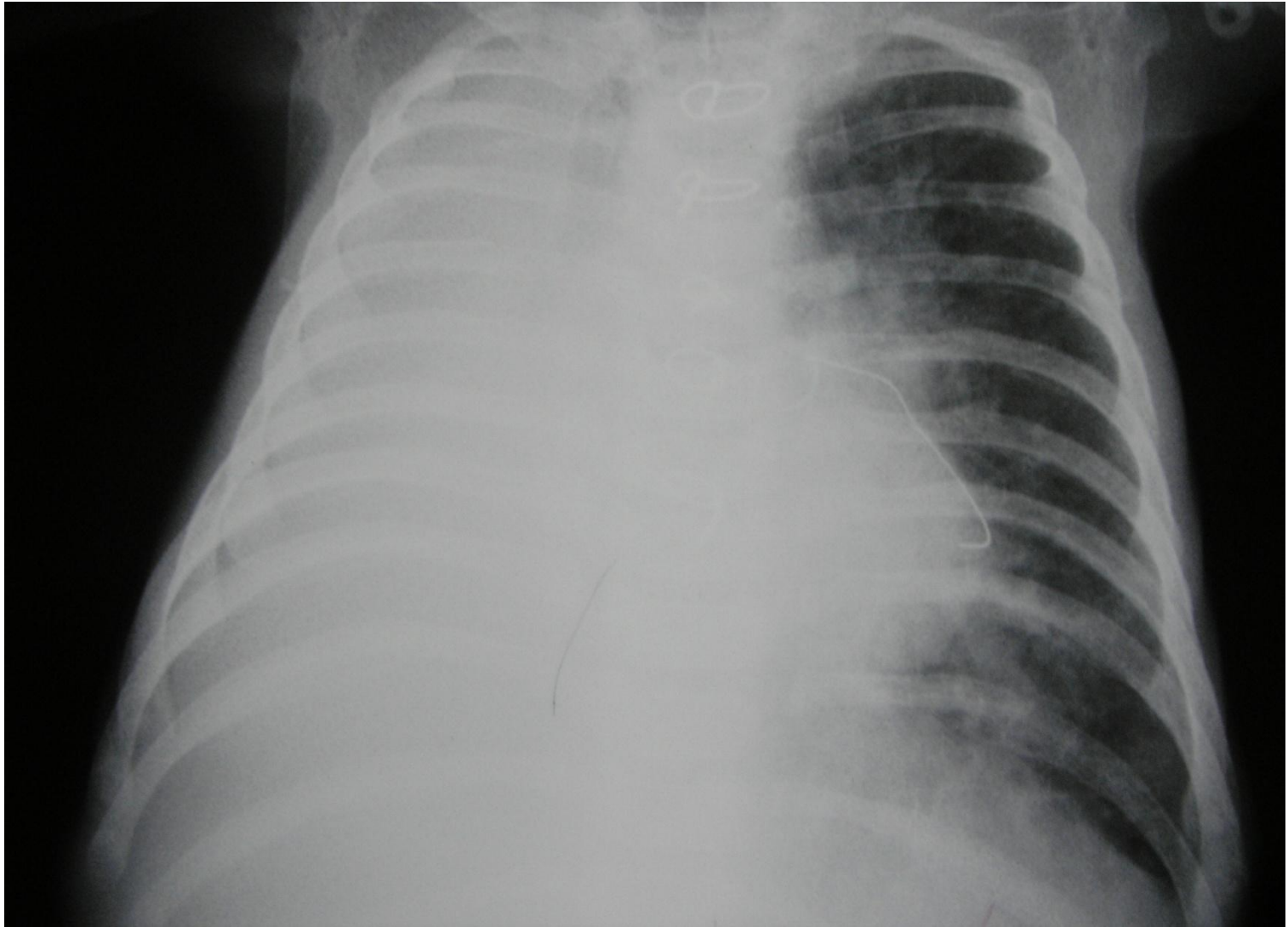


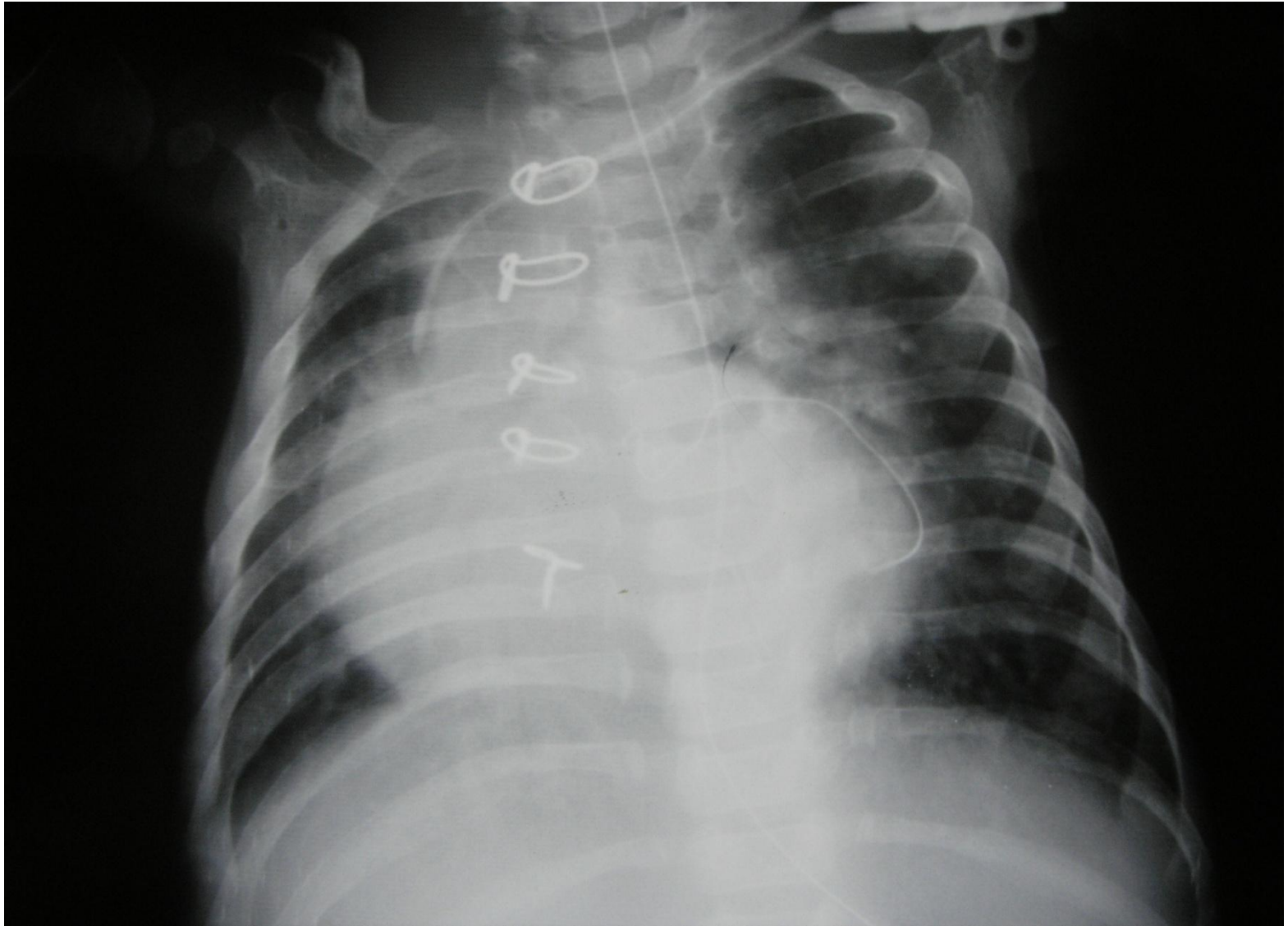
Konjental pnömoni-Kontrol

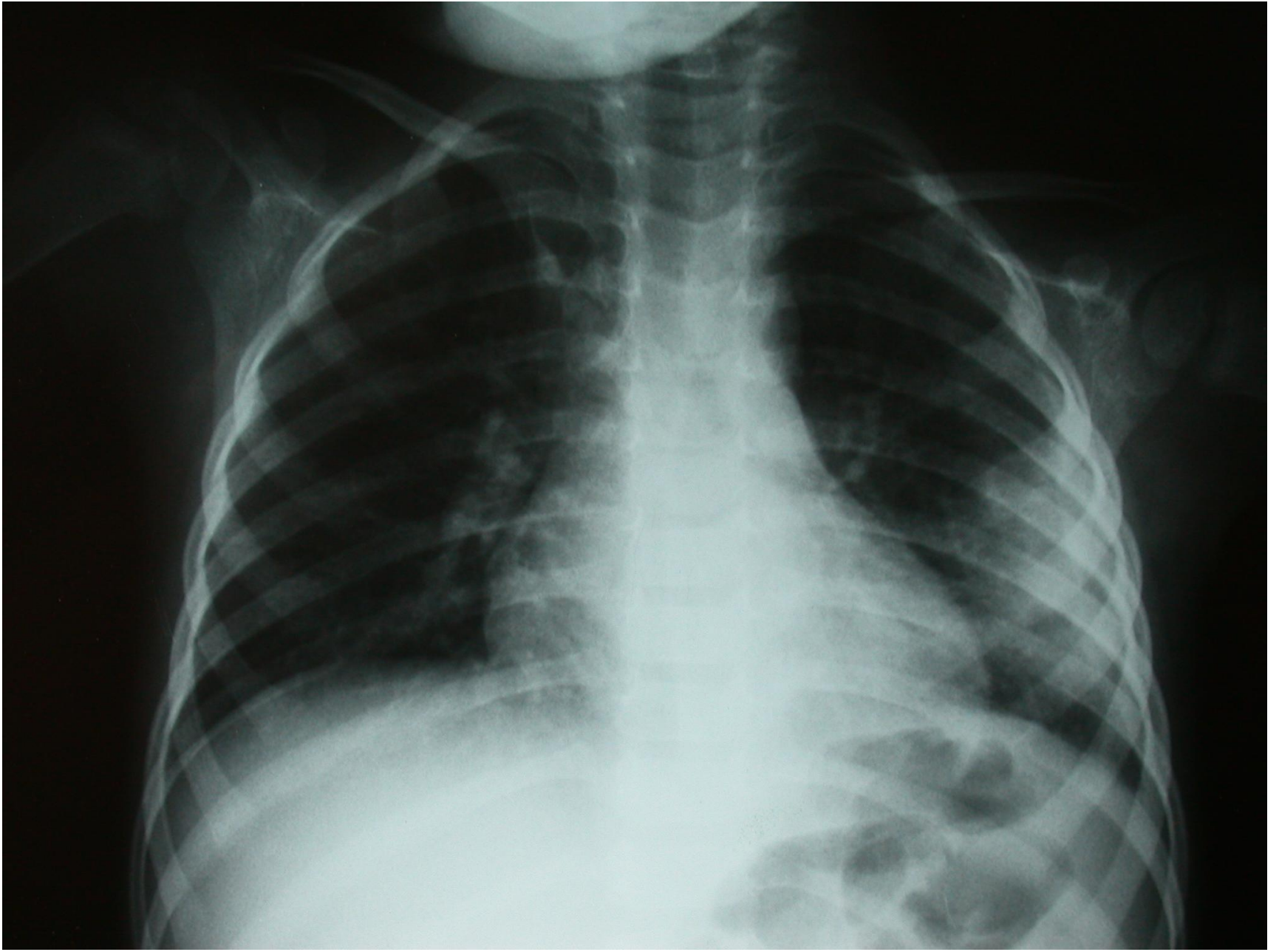




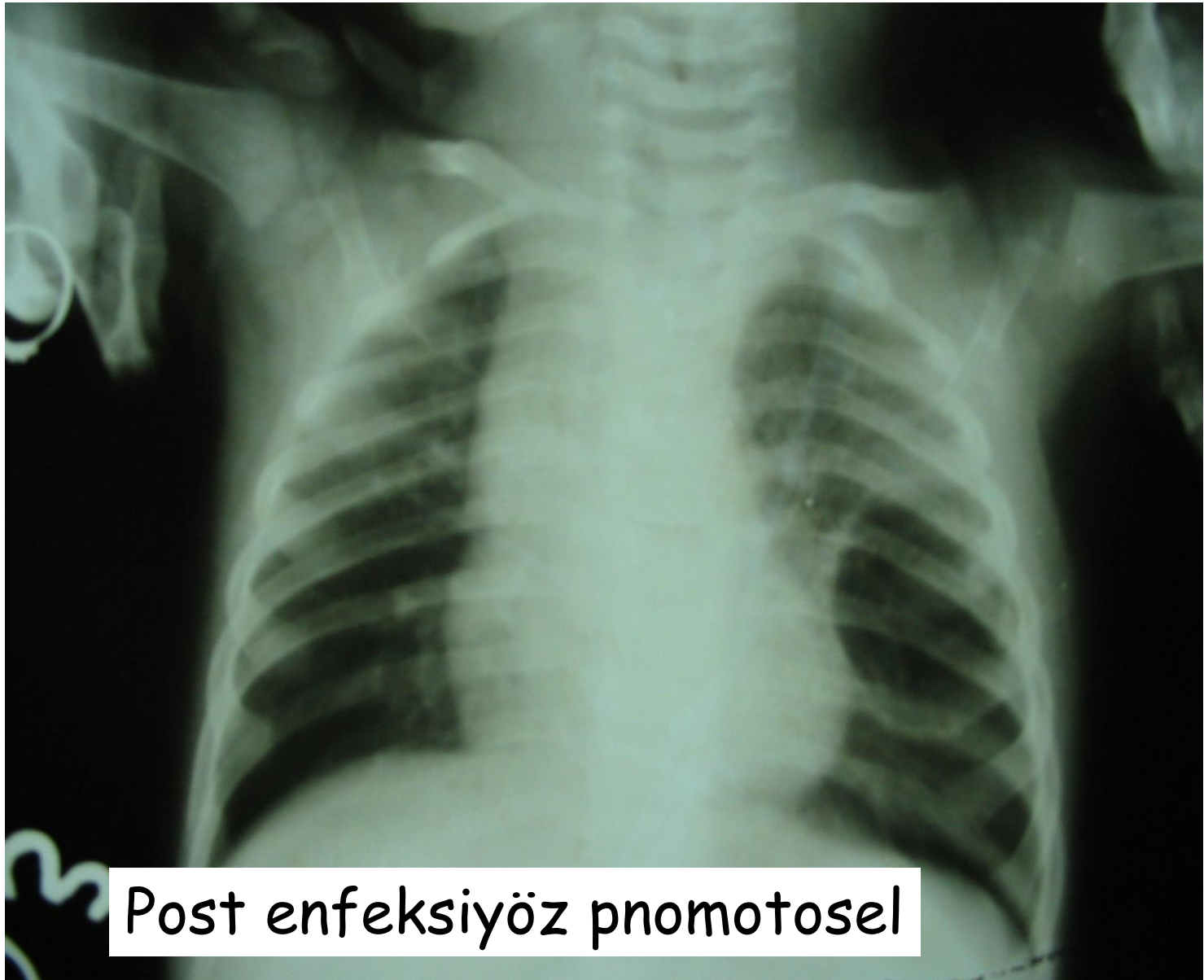CK 3 yaş kız hasta,
Klebsiella Pnömonisi



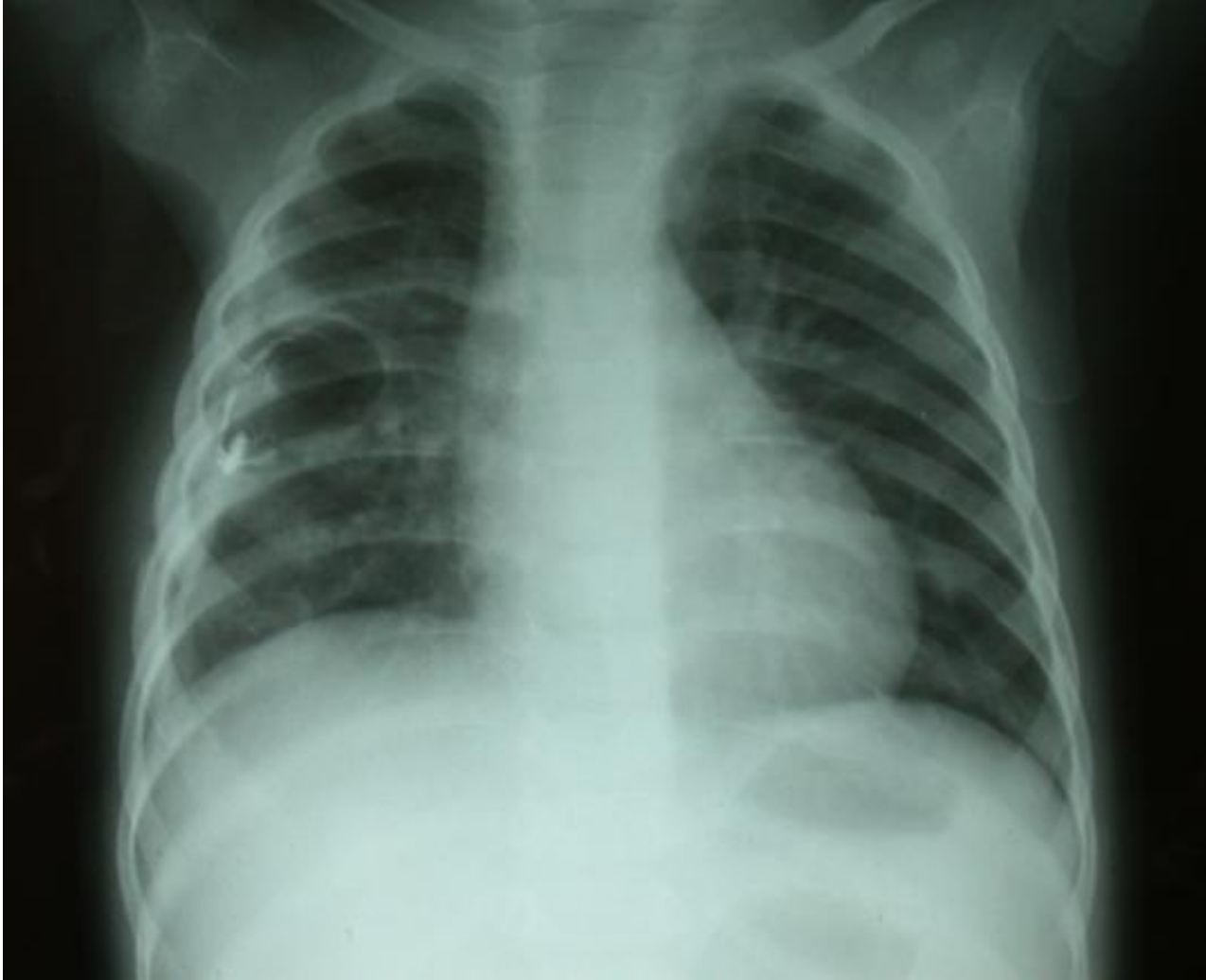



ZO 3 yaş kız hasta pnömoni

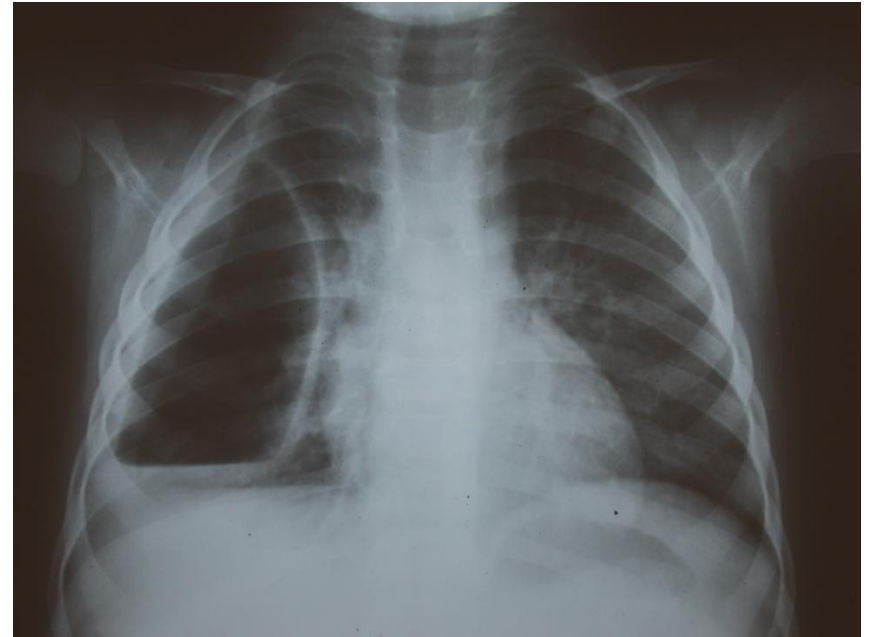
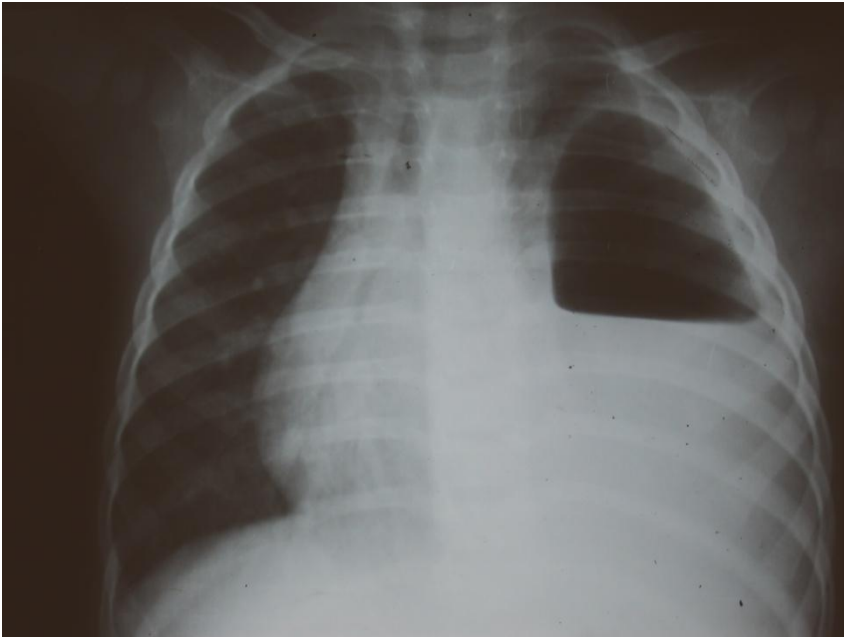


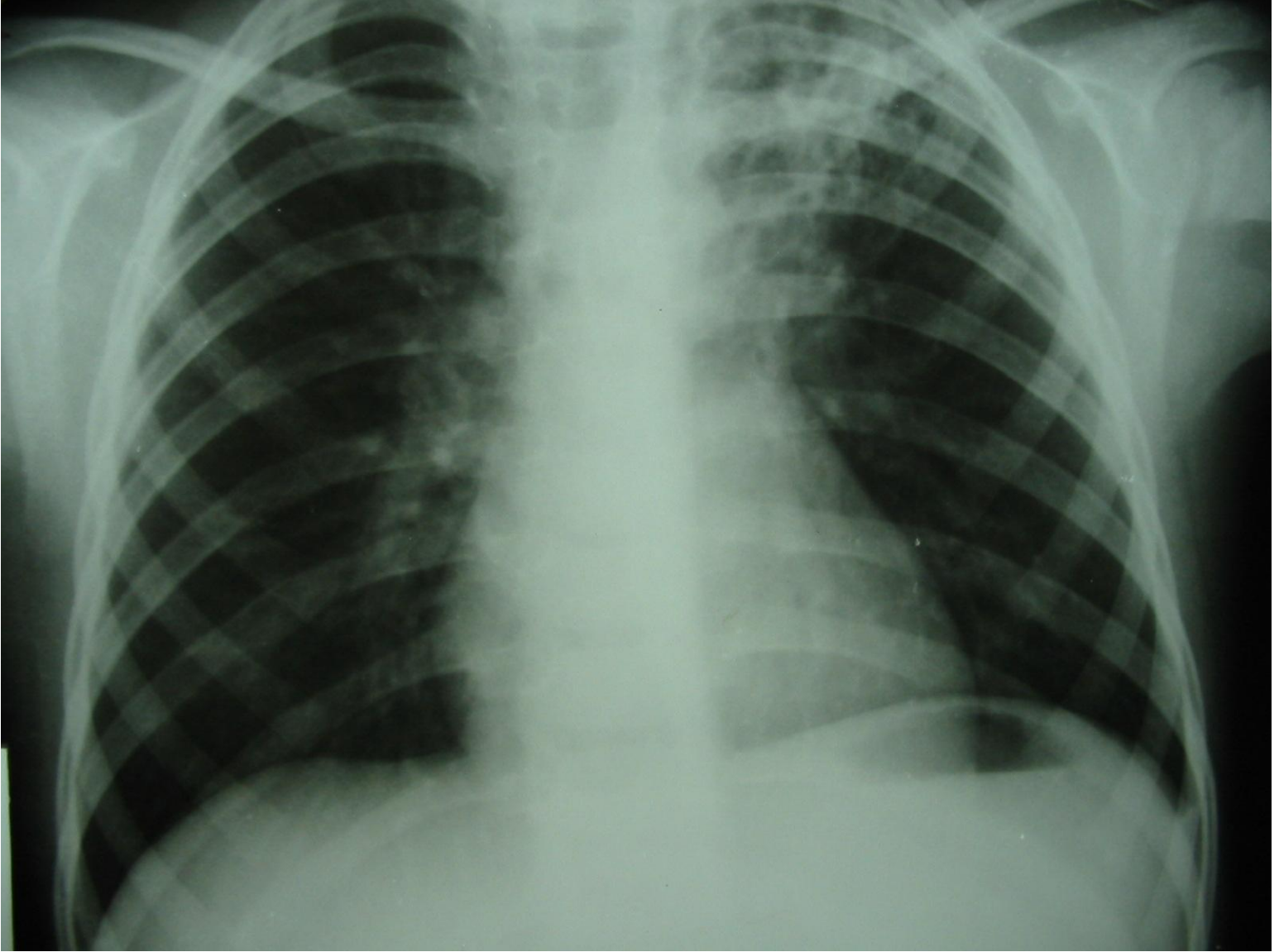
Post enfeksiyöz pnomotosel



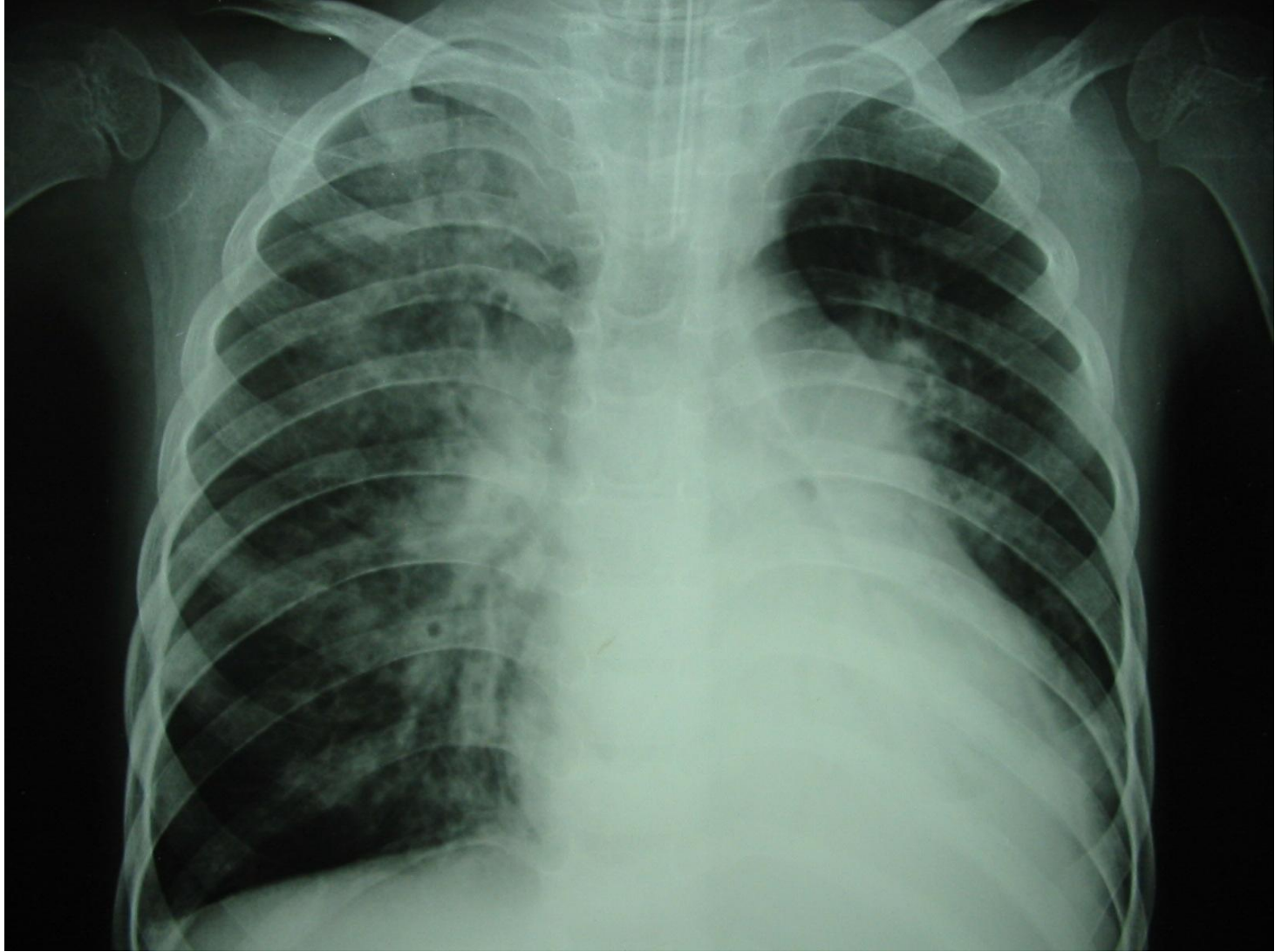İC 5 yaş erkek hasta post enfeksiyöz pnomotose

Pnömatosen

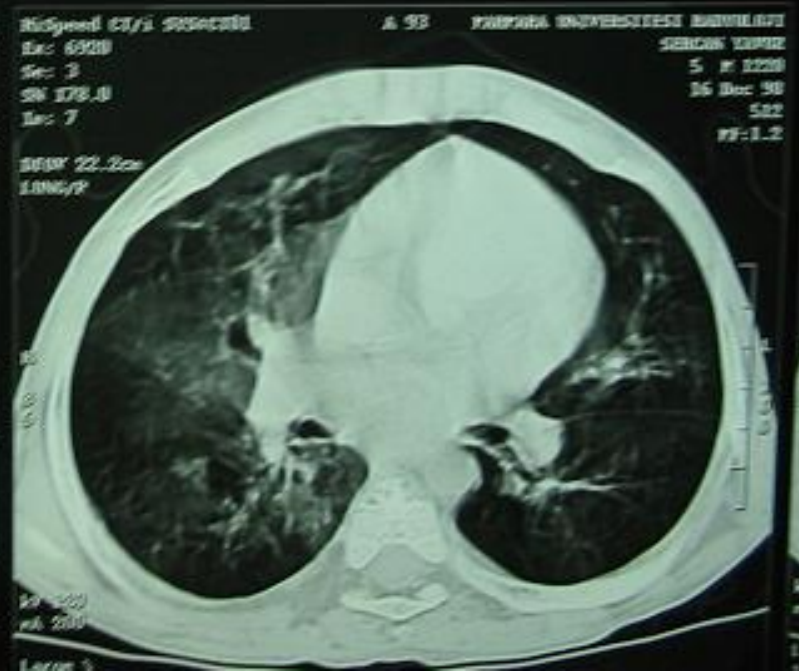
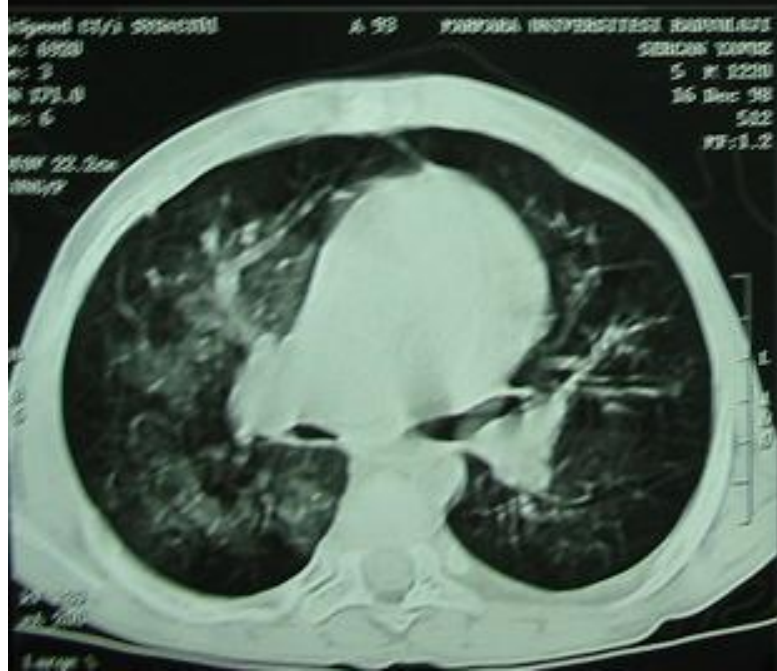
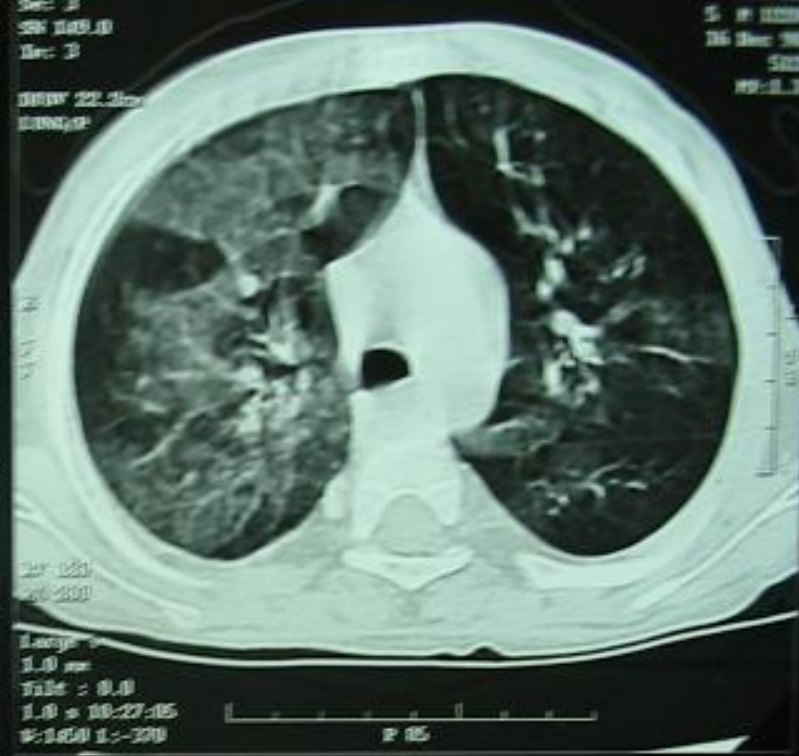
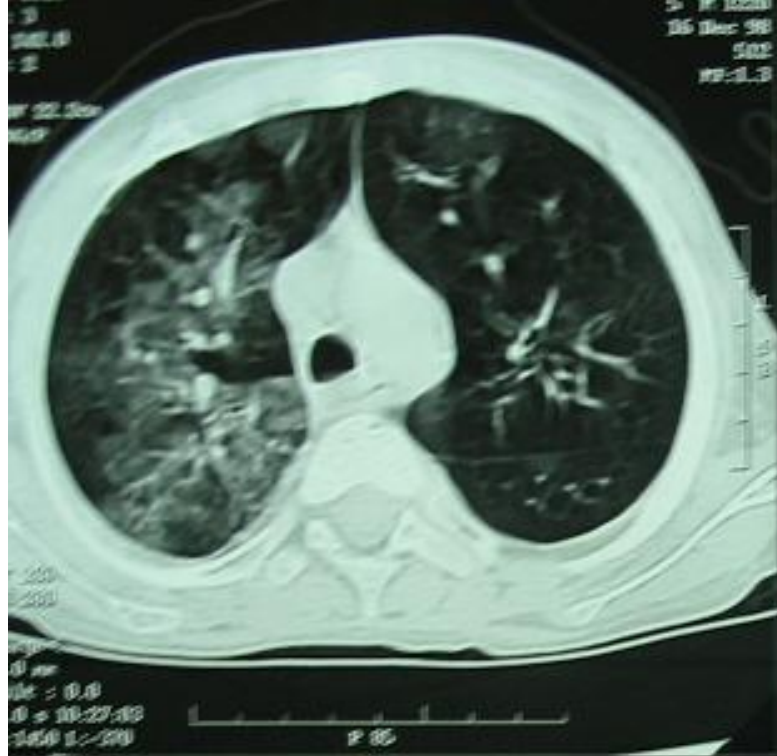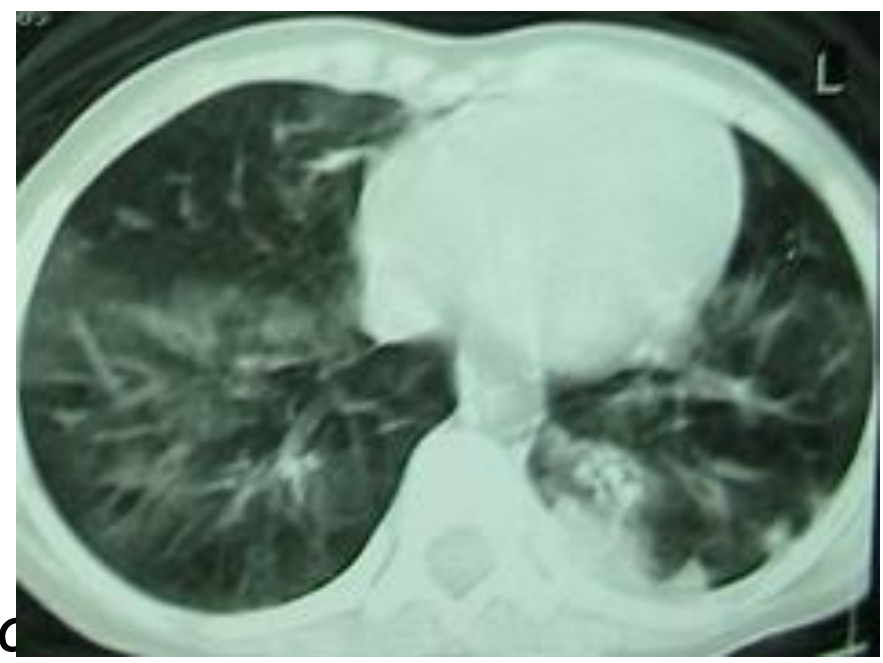
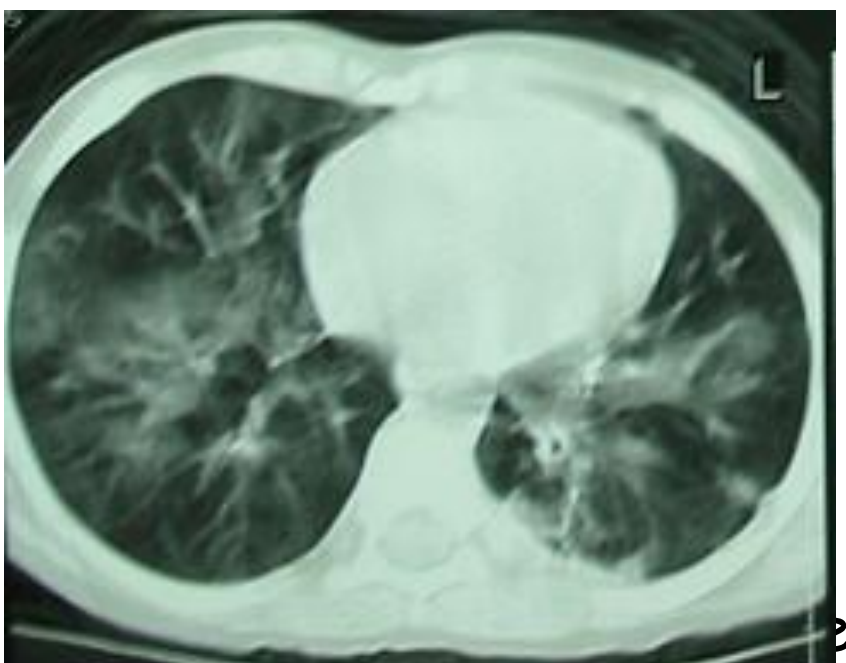
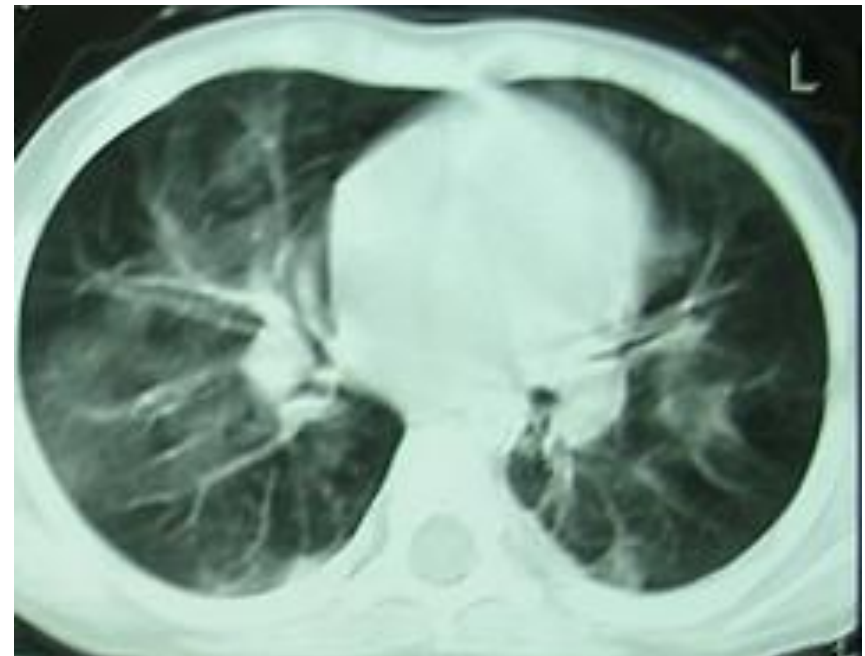
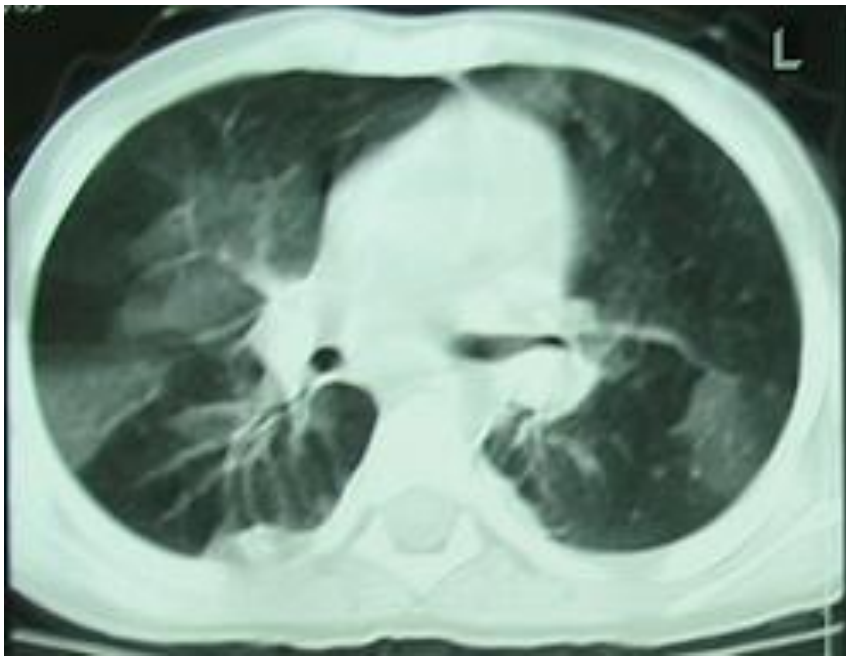


Sol üst lob Post enfeksiyöz bronşiektazi

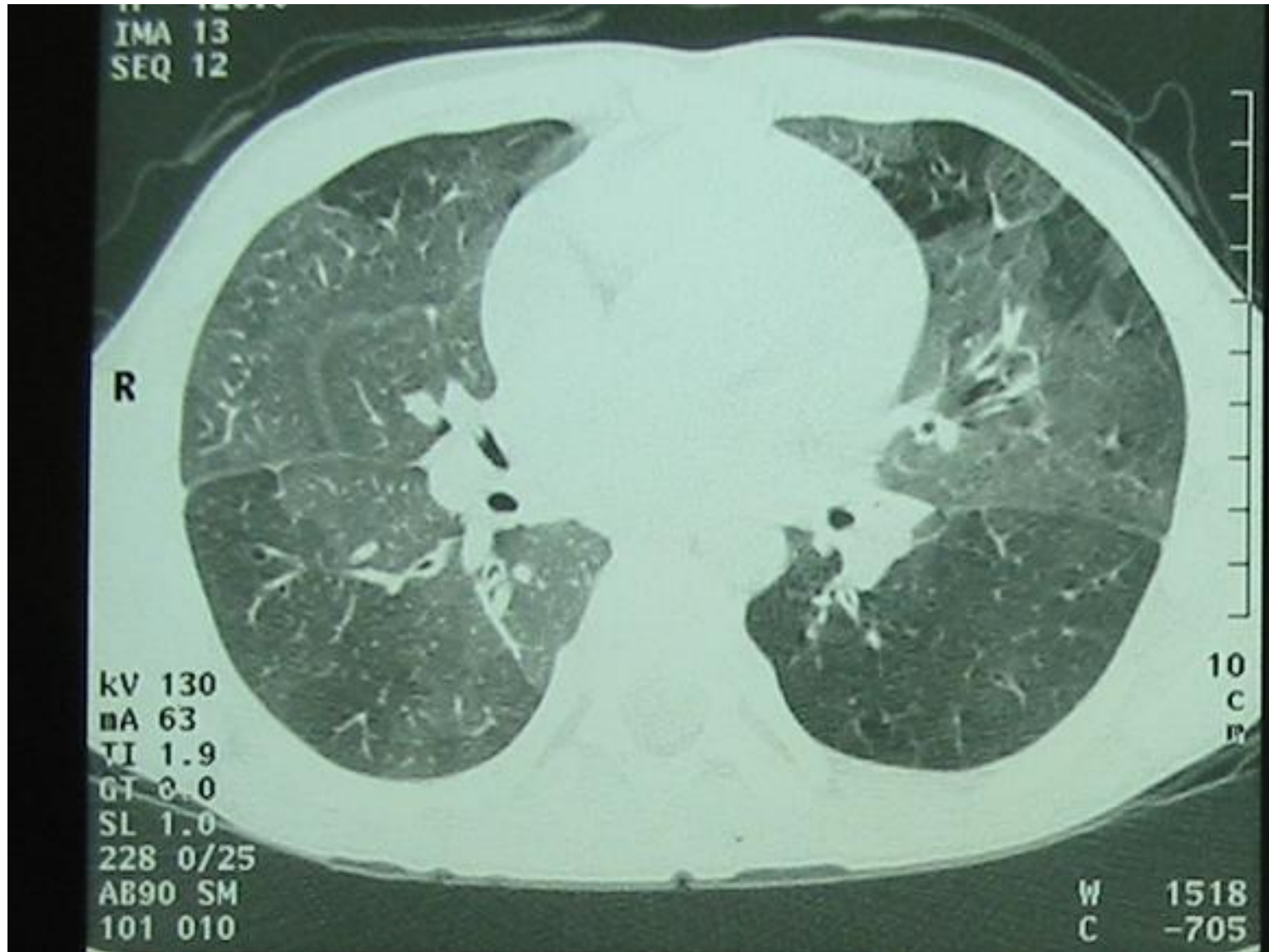


Bronşiolitis Obliterans (Kızamık Sonrası)

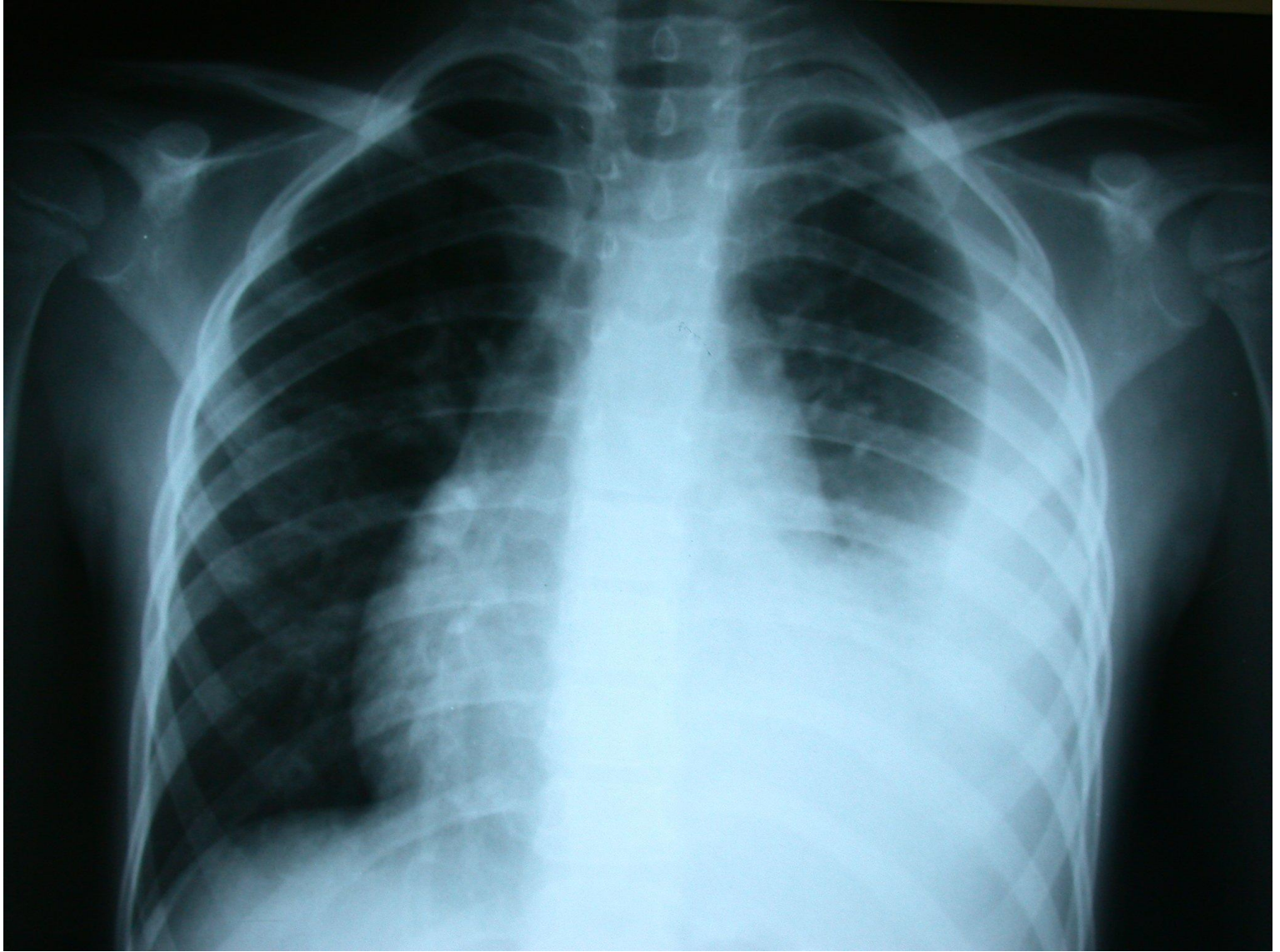




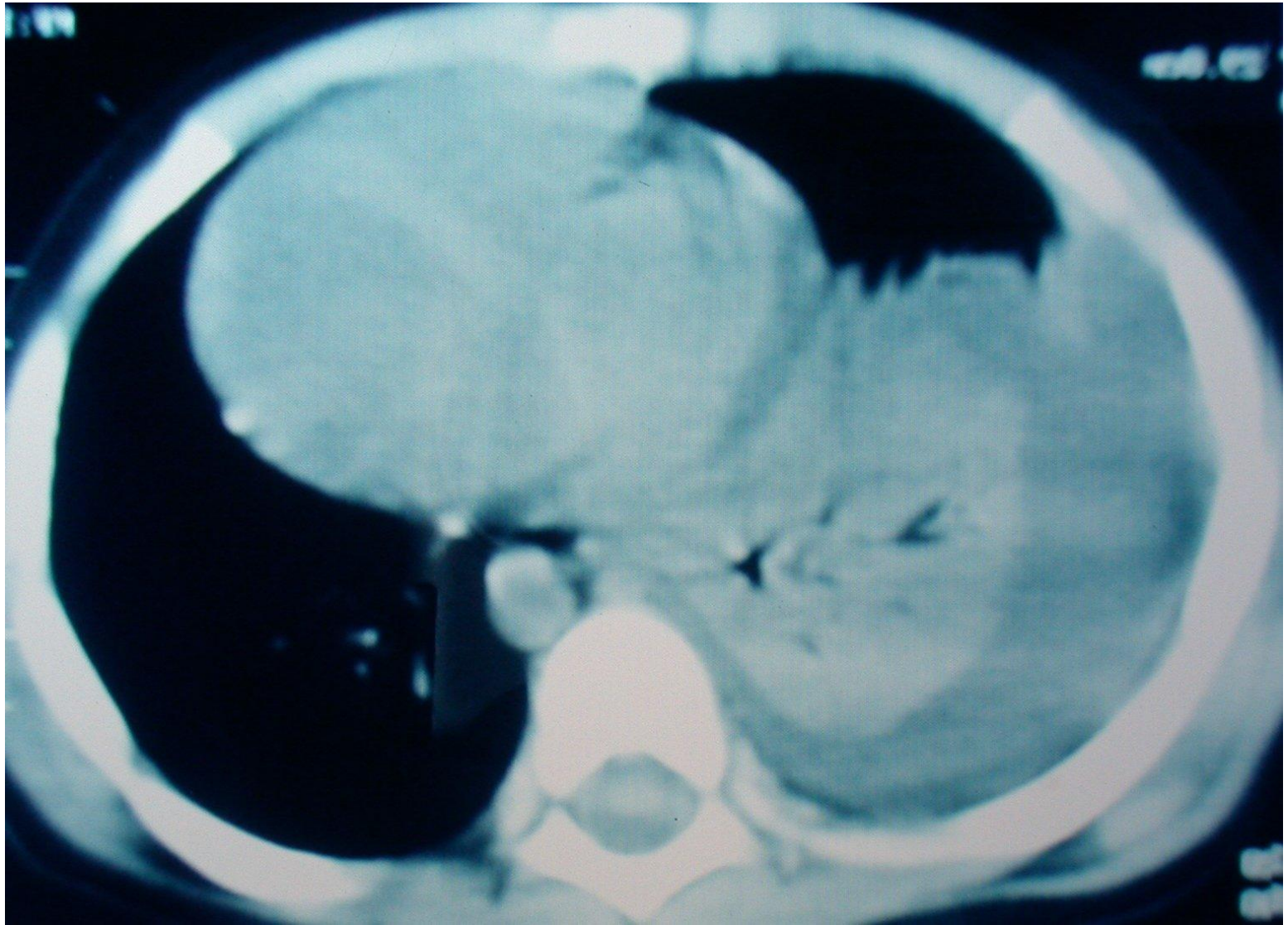erc



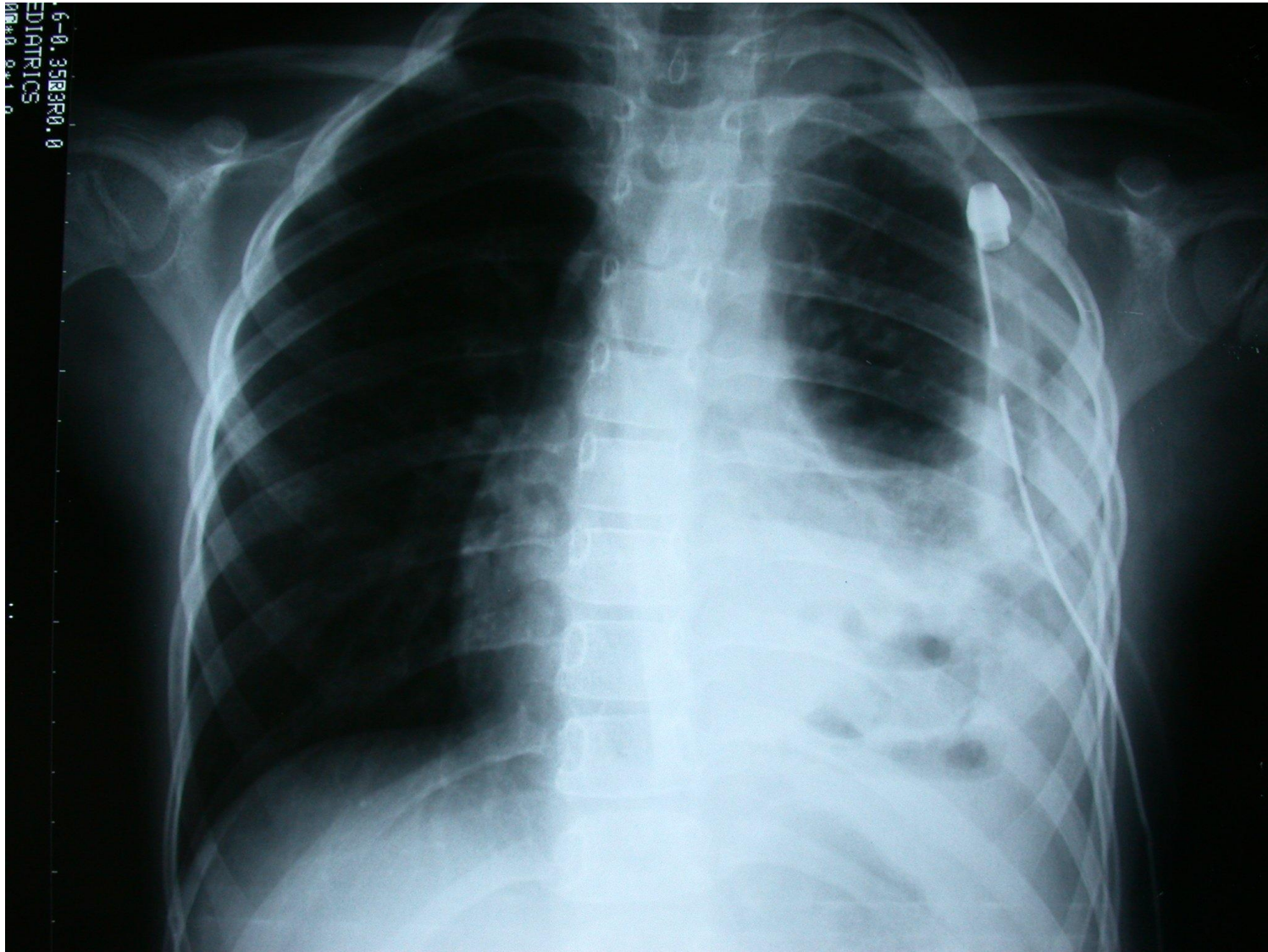
Bronşiolitis obliterans



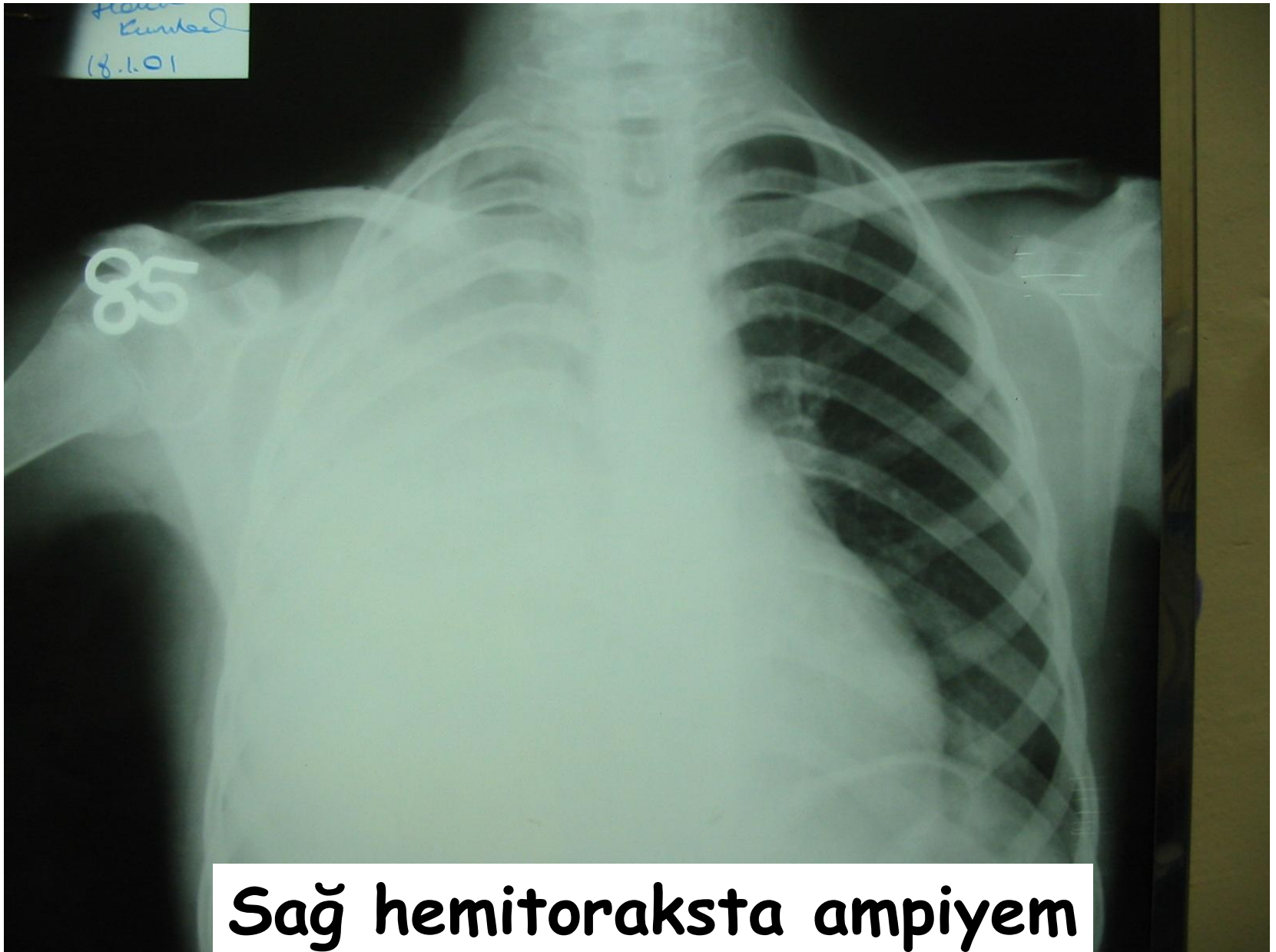Ampiyem



Ampiyem

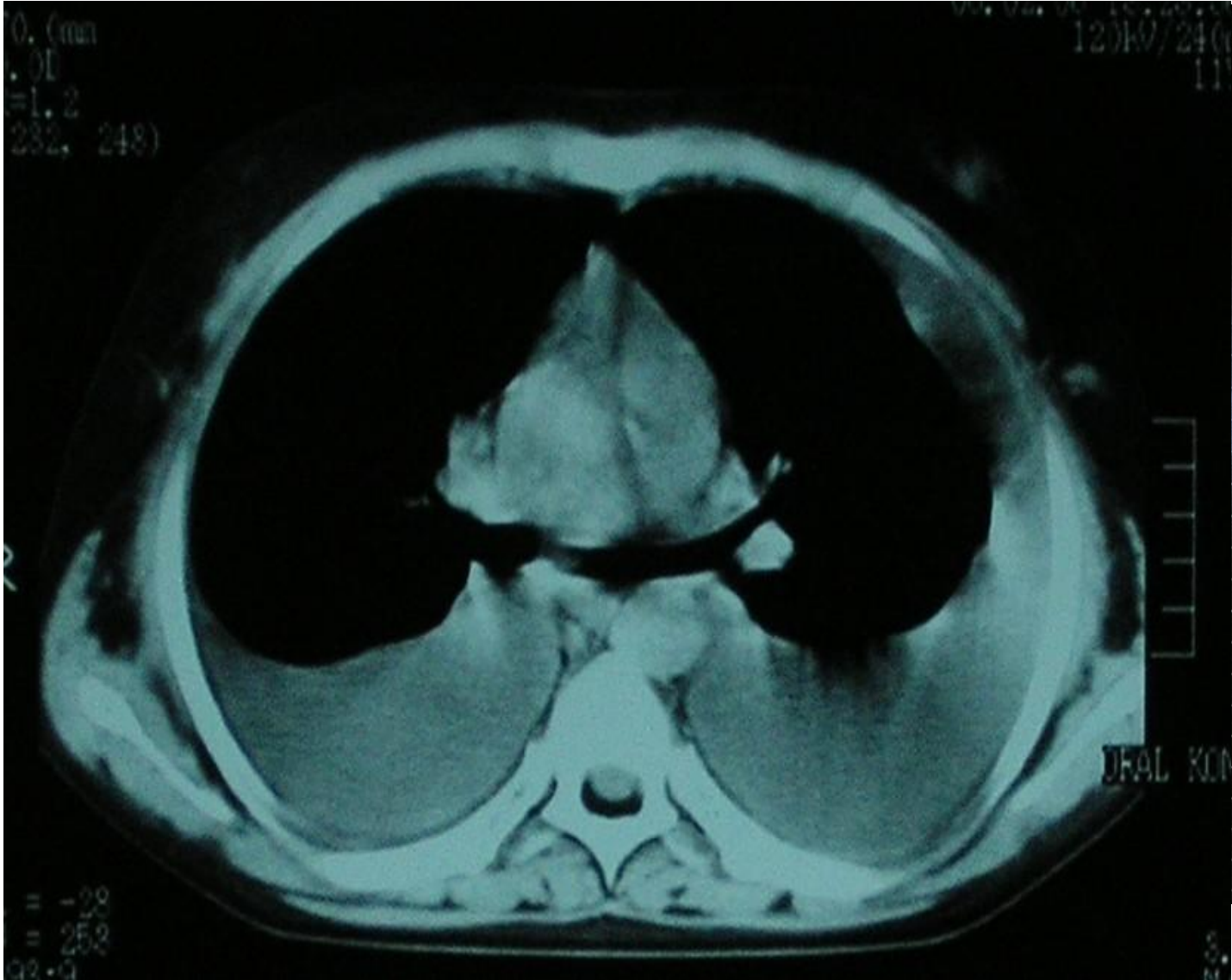


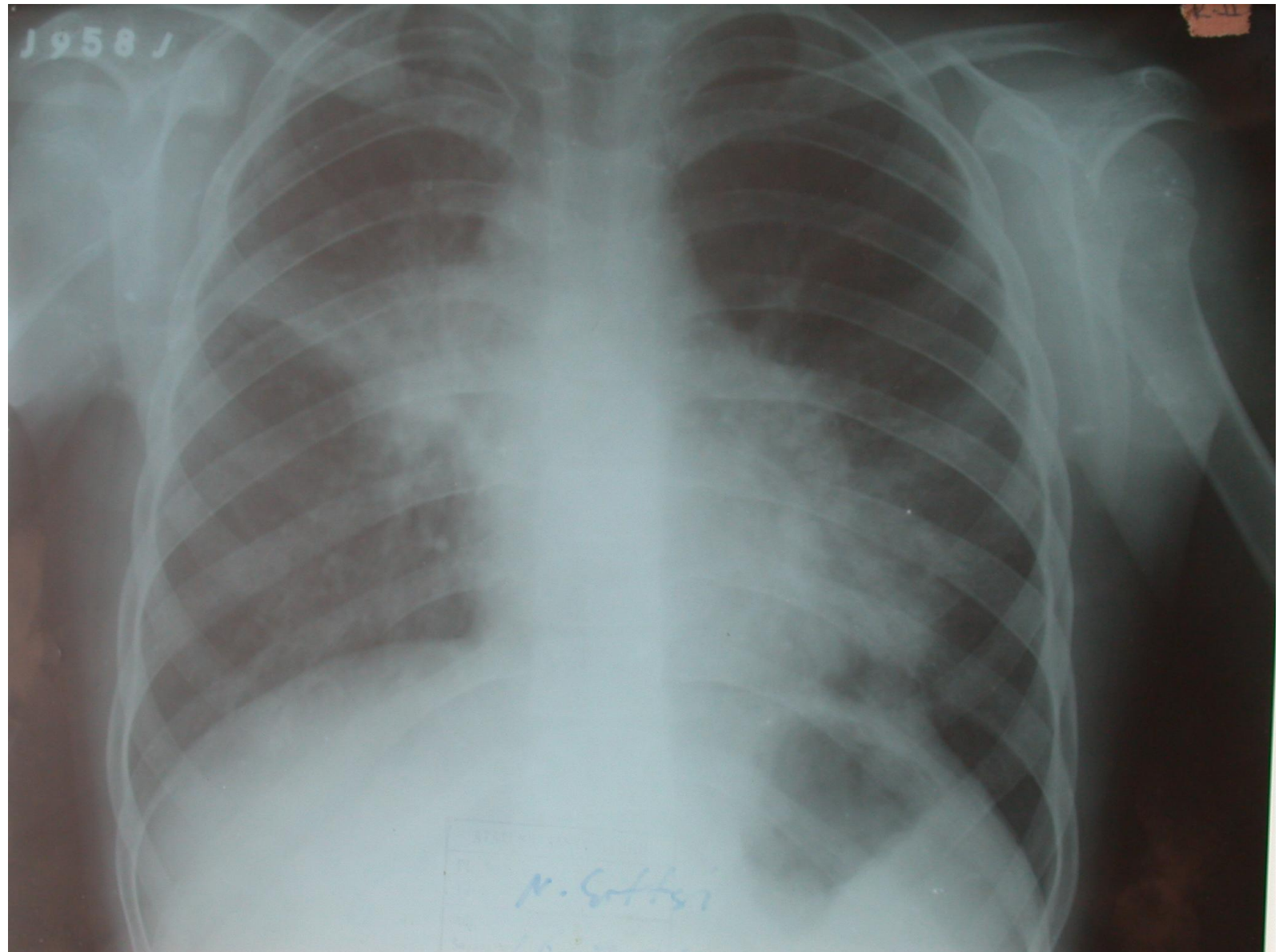
Ampiyem



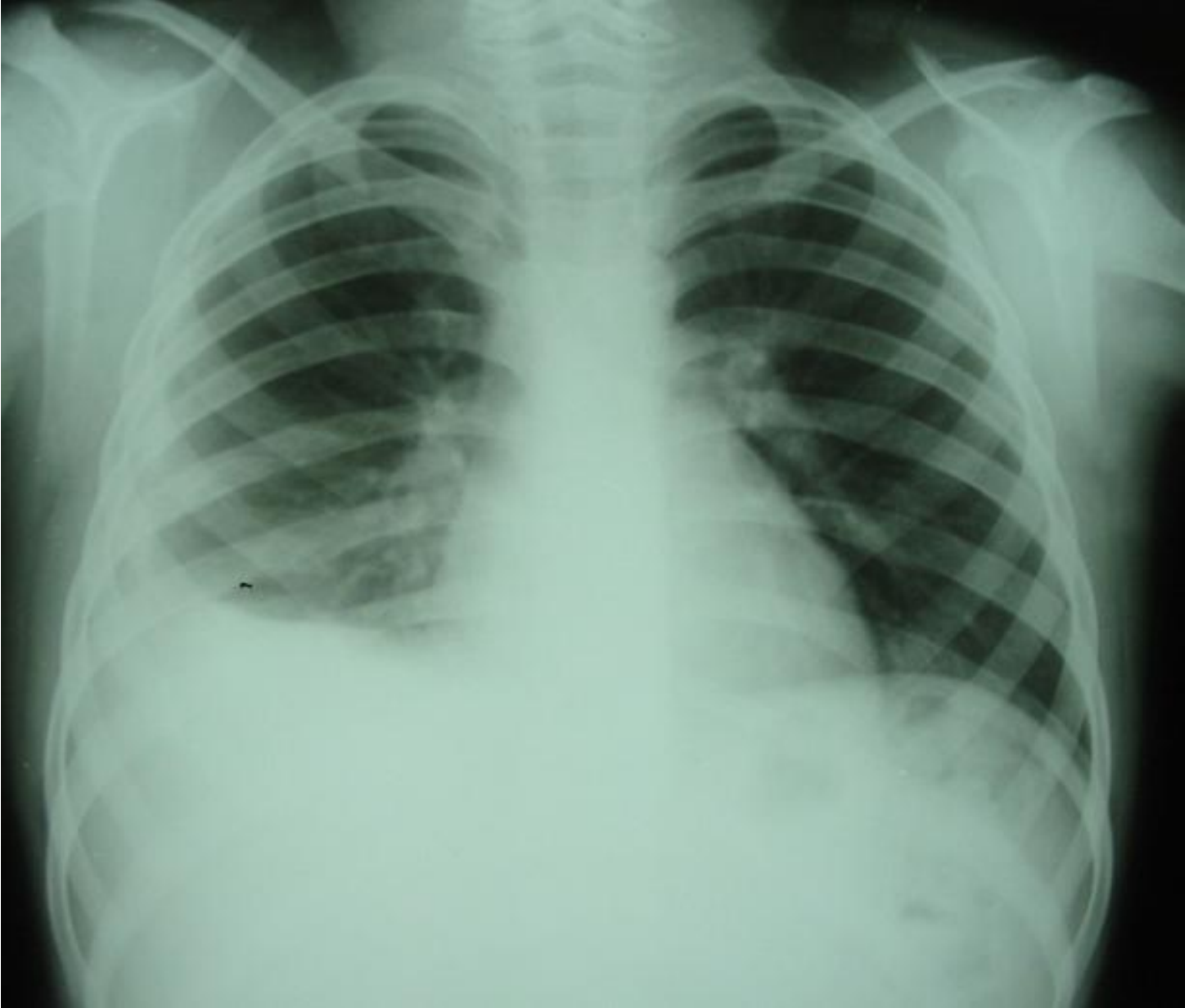Sağ hemitoraksta ampiyem

Bilateral Şilotoraks

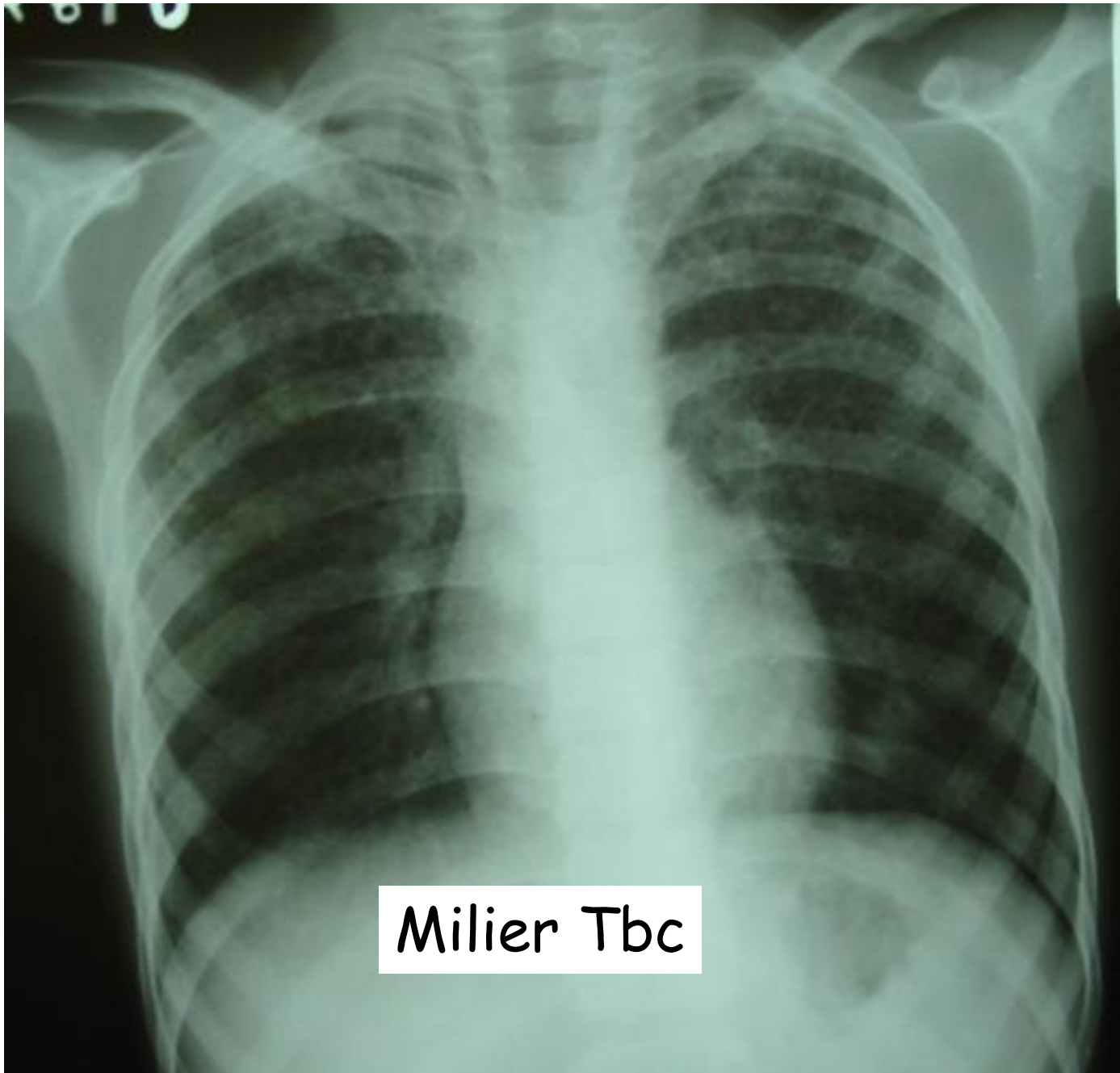




Tüberküloz

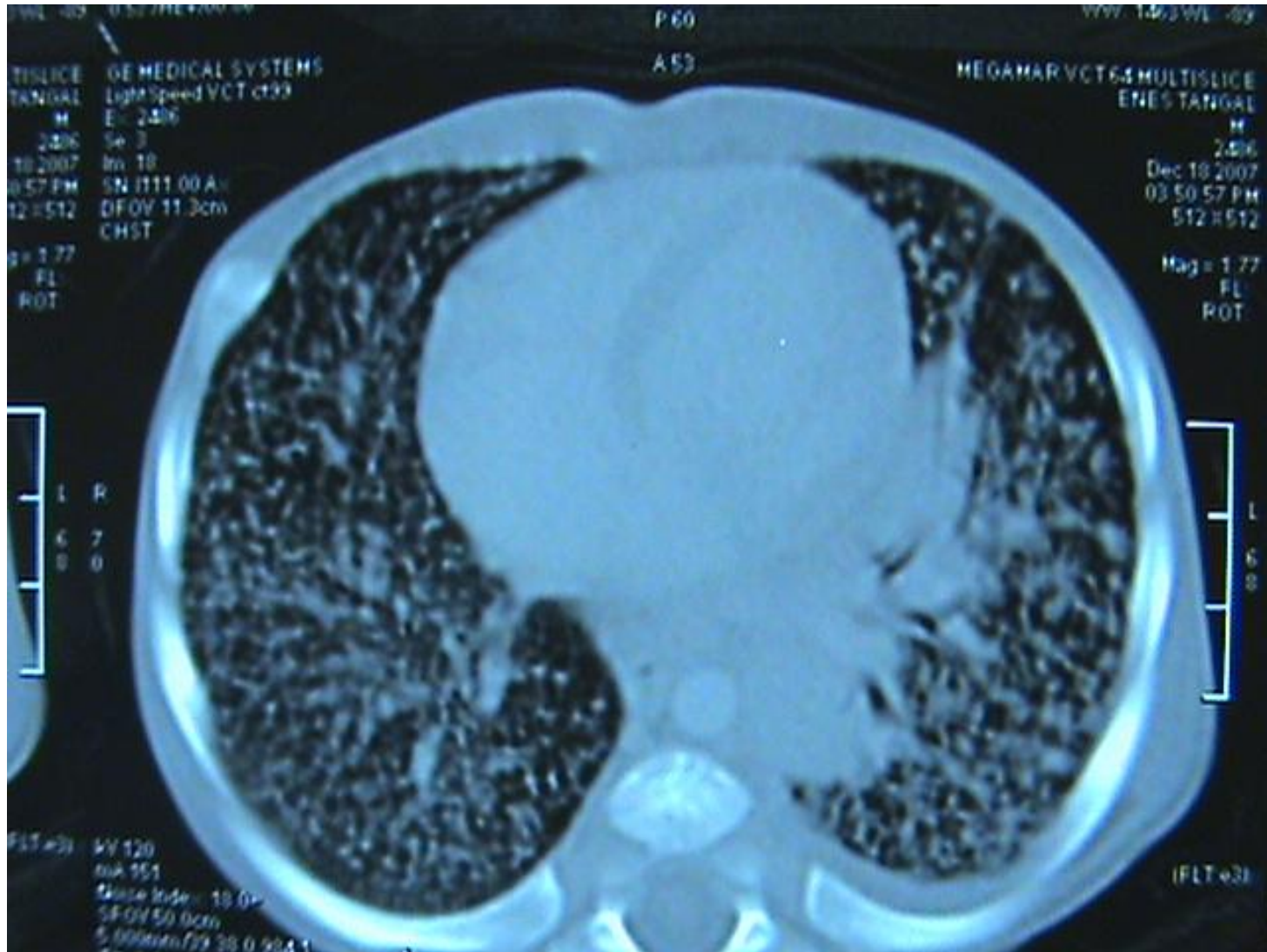


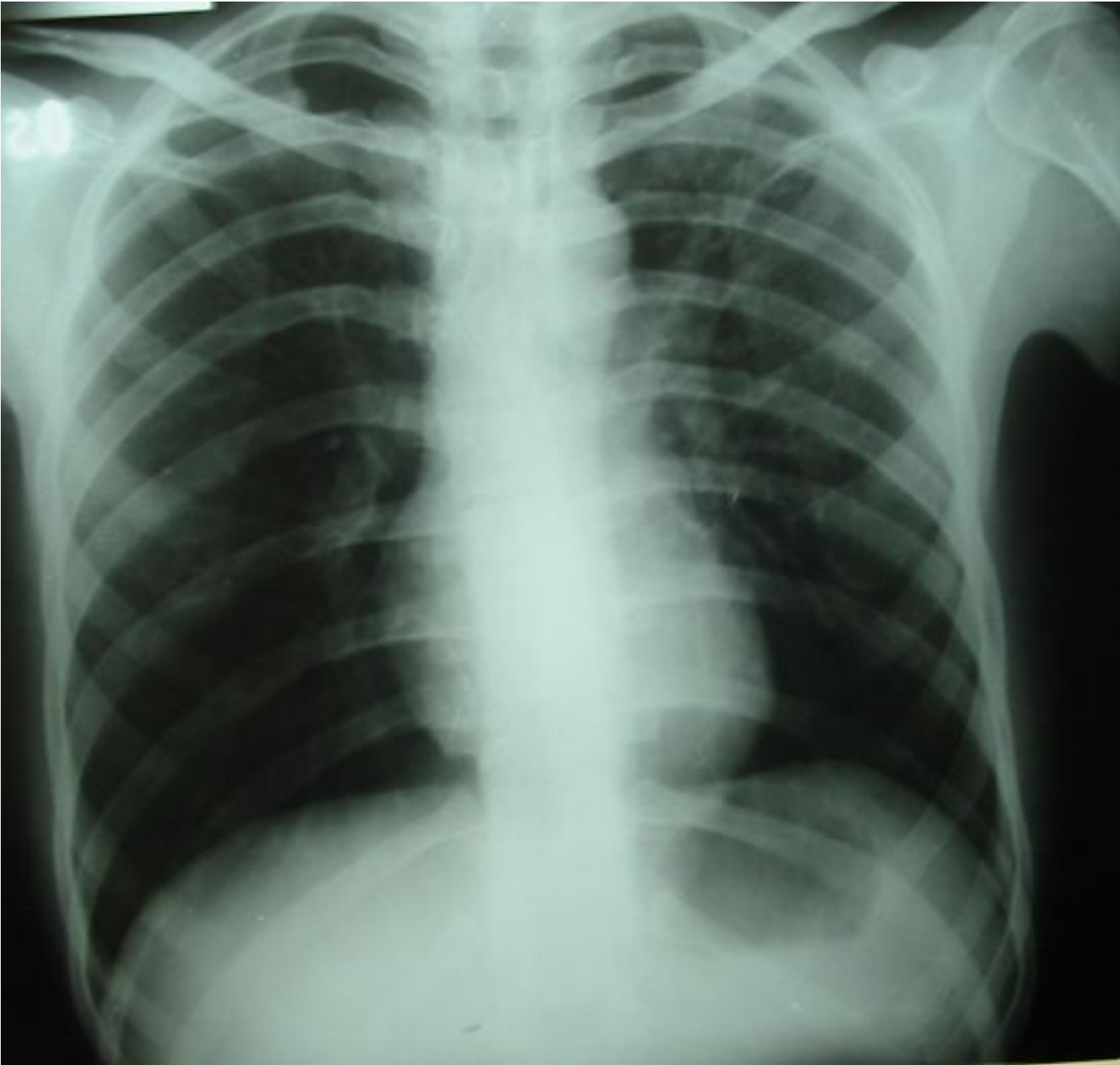Tüberküloz plörezi

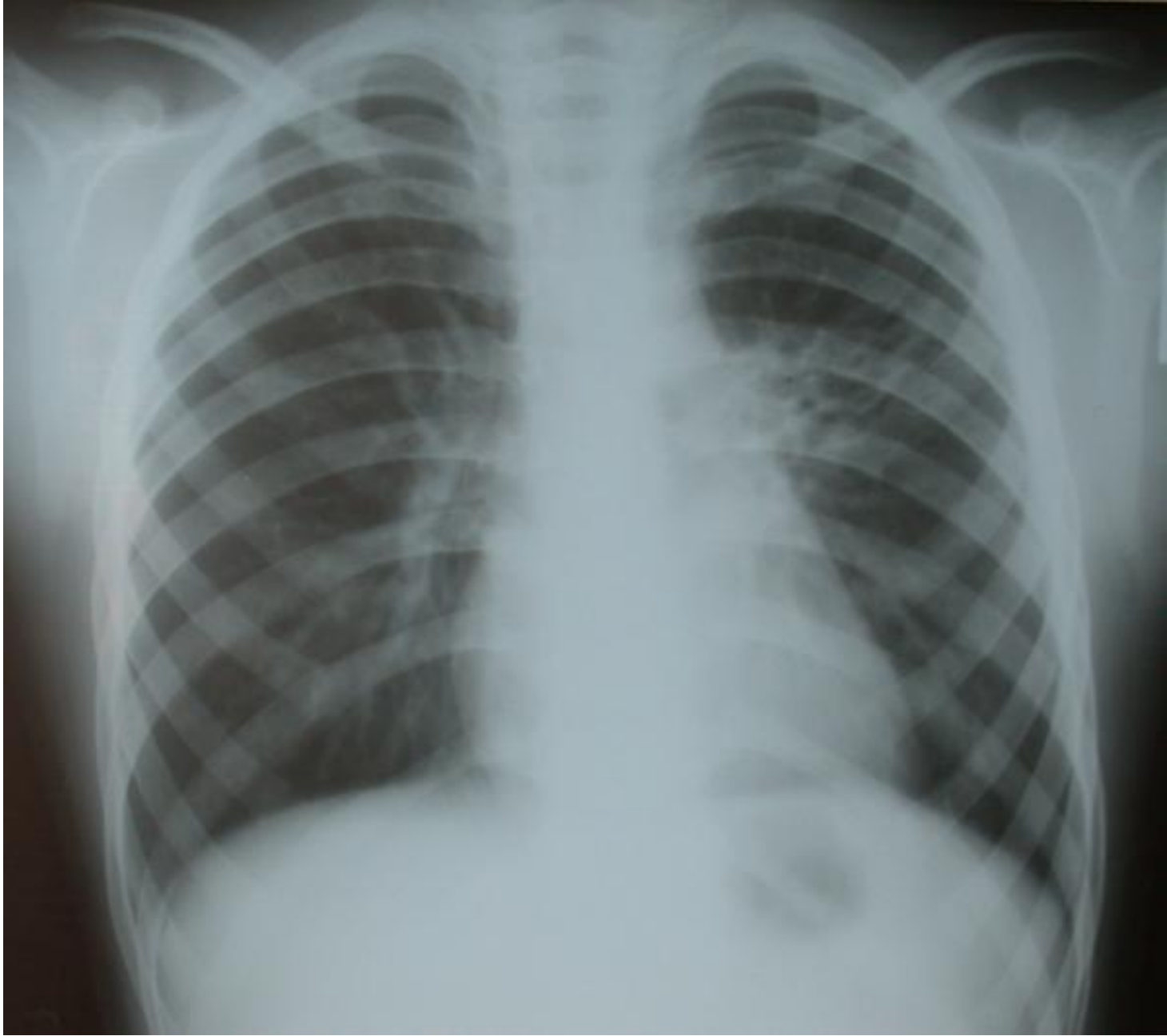

Milier Tbc

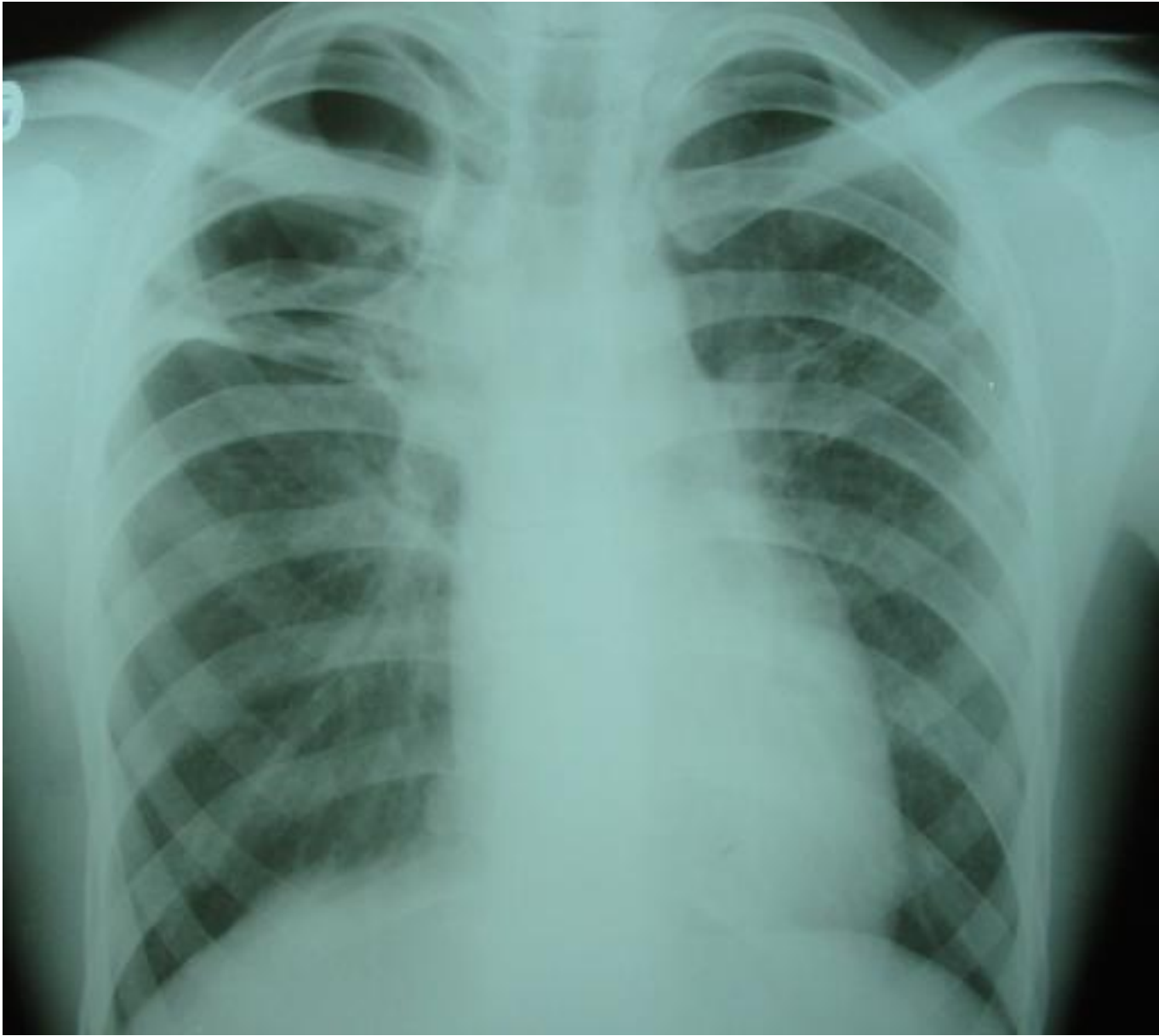
Milyer TB



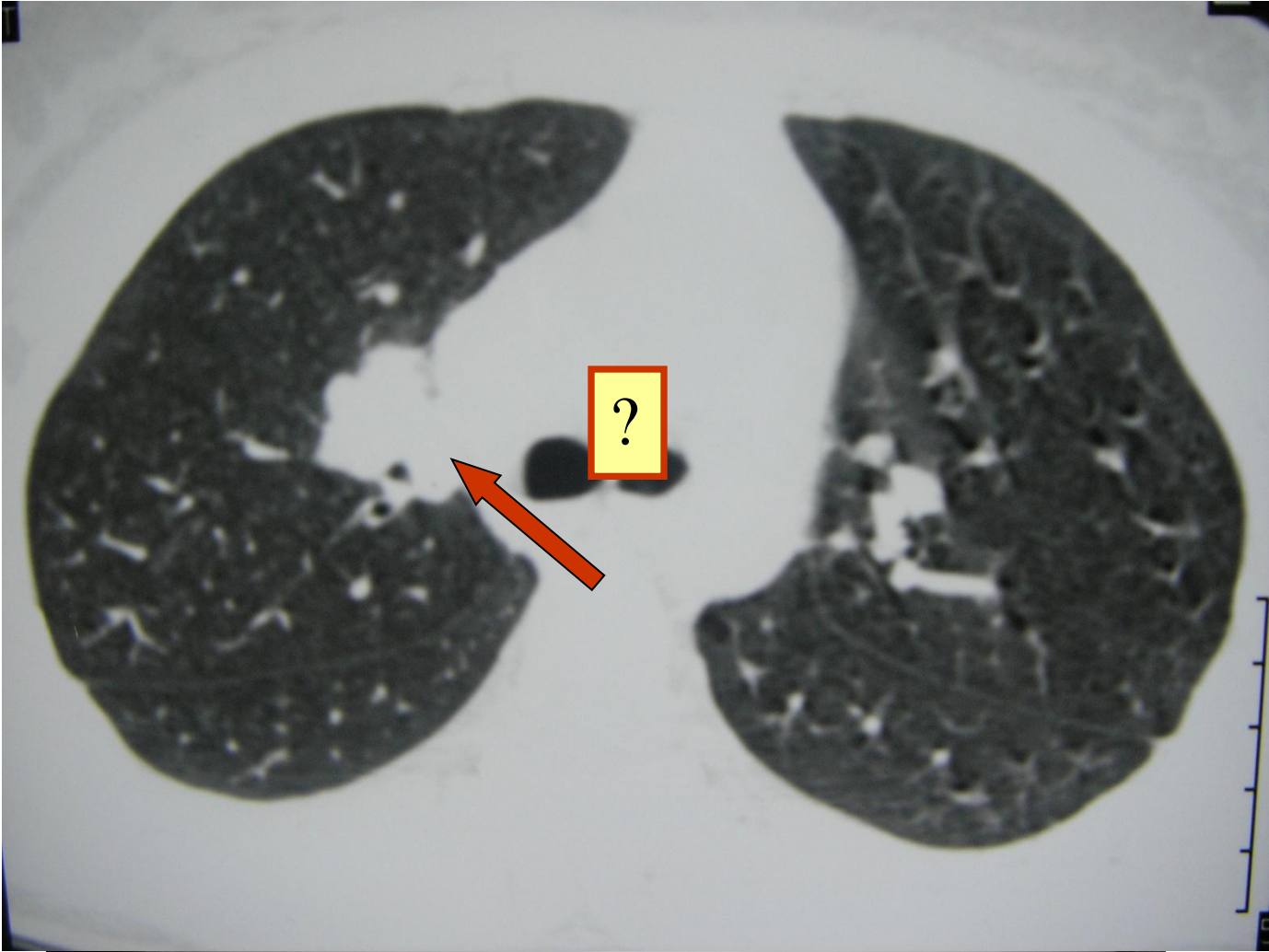




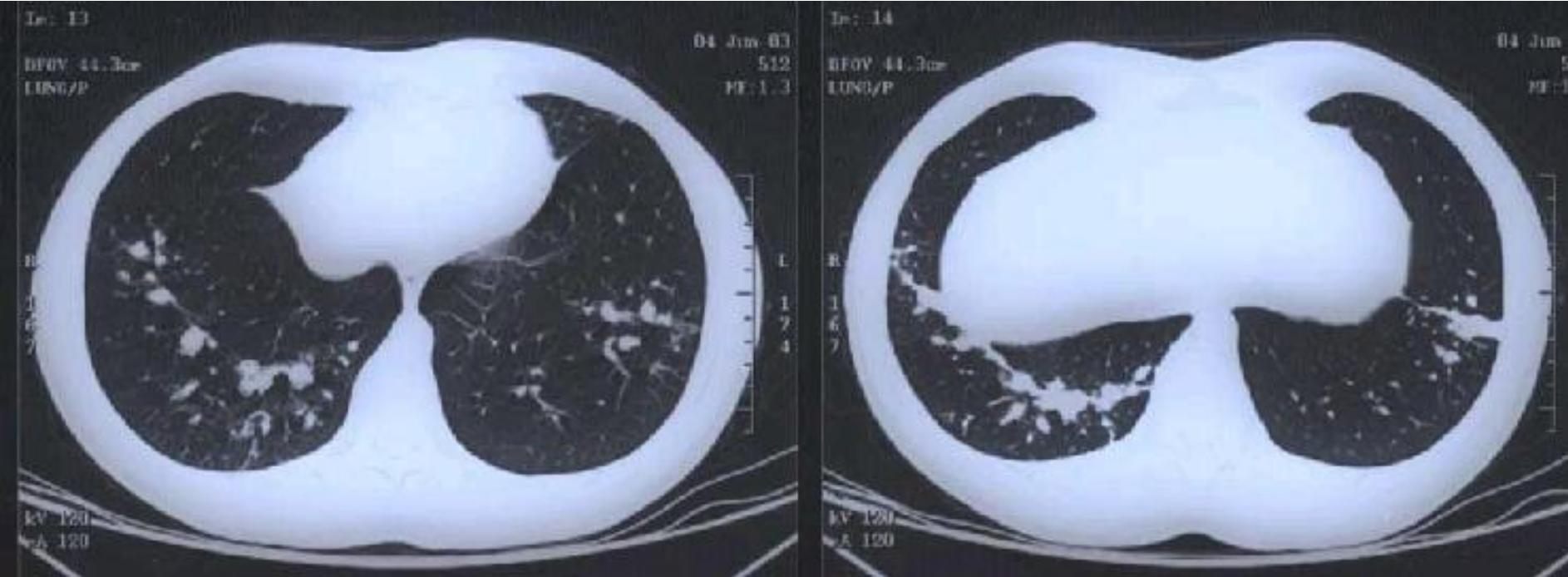
OK 3 yaş erkek hasta, Tüberküloz



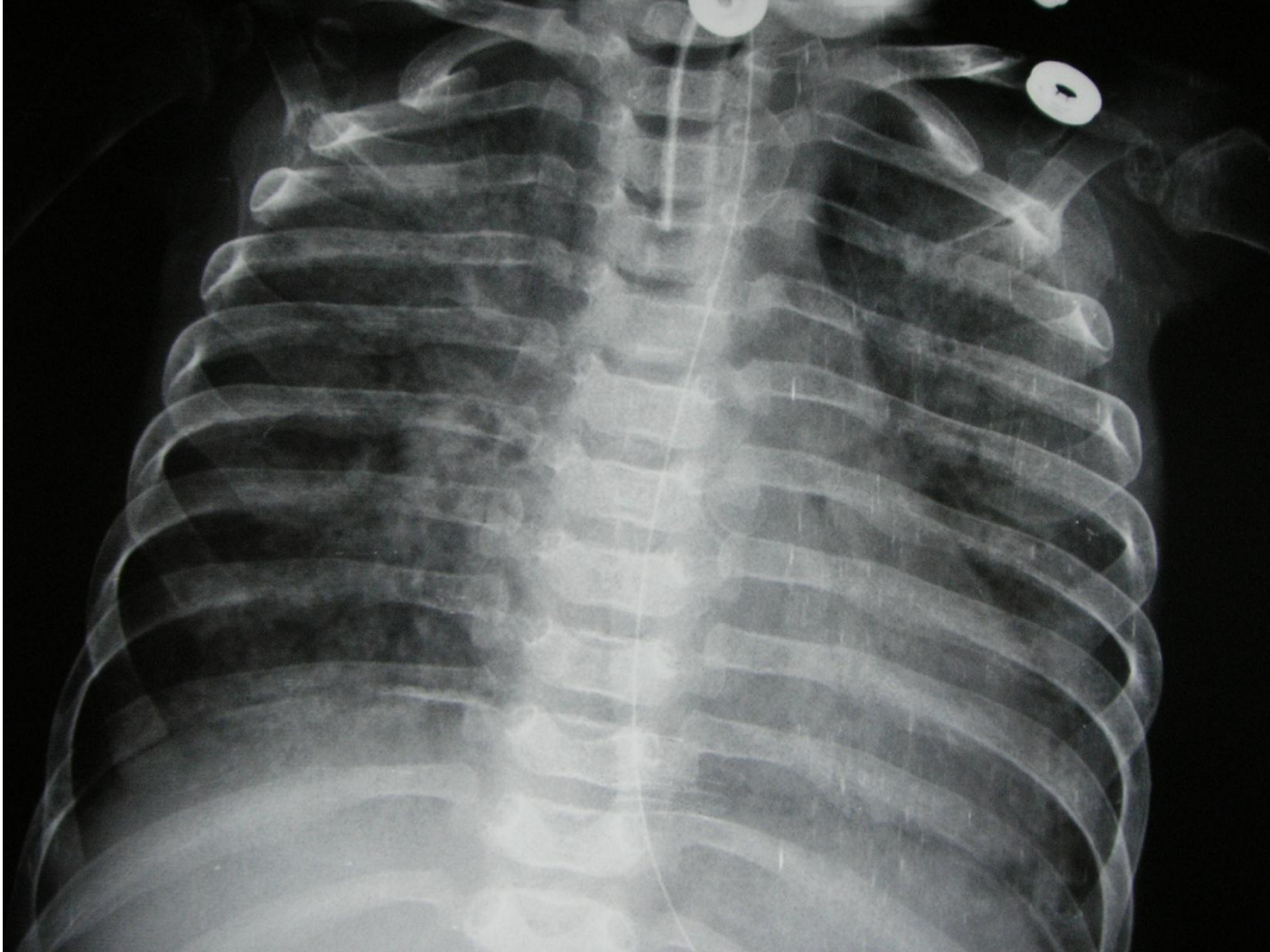
Tüberküloz



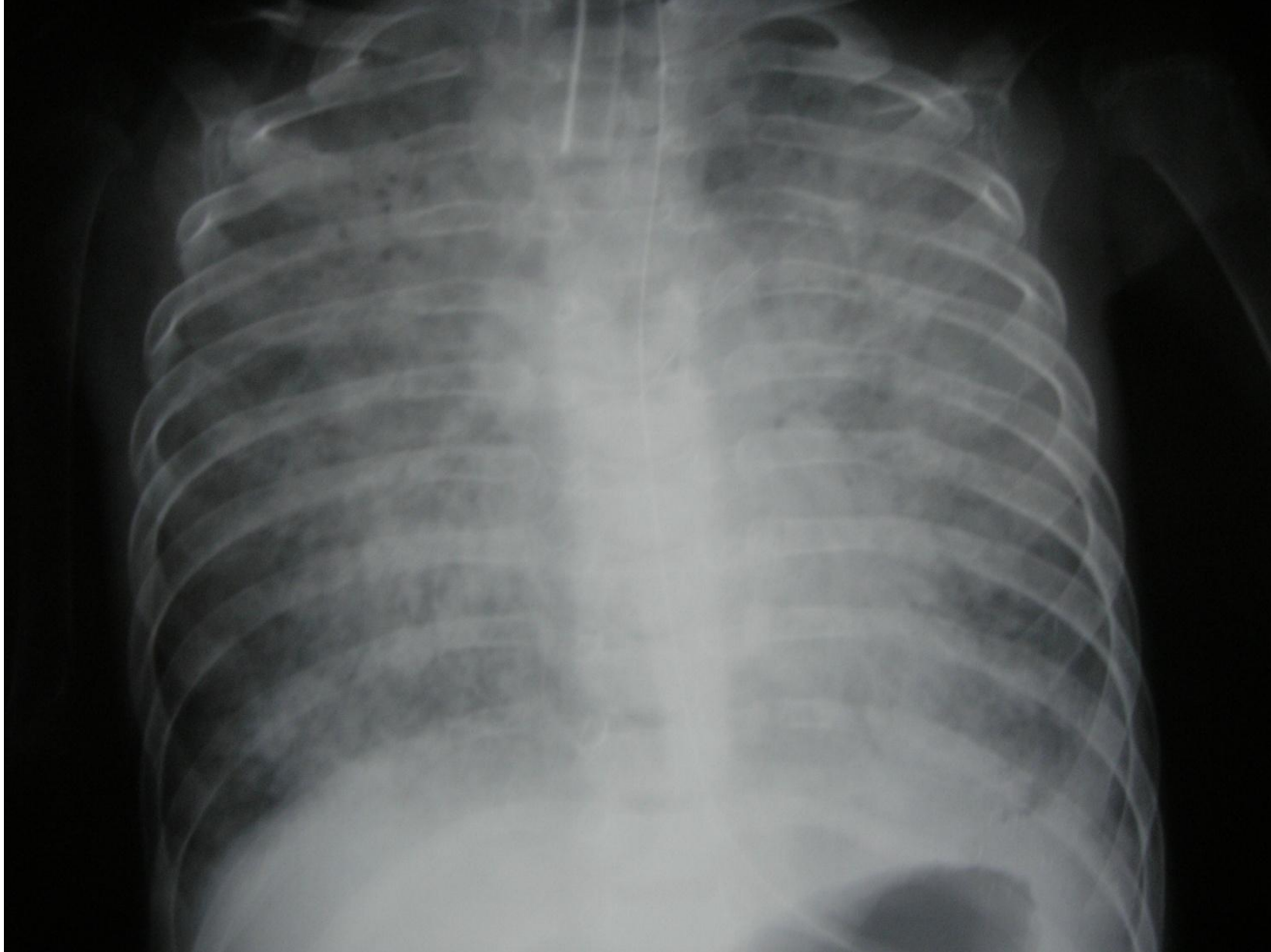
EB Tüberküloz ve masif hemoptizi



E.B İnterstisyel Akciğer Hastalığı



E.B İnterstisyel Akciğer Hastalığı



MELIHA YILMAZ

20990

01-JAN-1987

18-SEP-2001

14:56:01.75

TP -173.5

MEDMAR Goruntuleme Mer

SOMATOM Balance

VA10D

H-SP-CR

SEQ 27

R

MF 1.20

KV 130

mA 55

TI 1.0

GT 0.0

SL 1.0

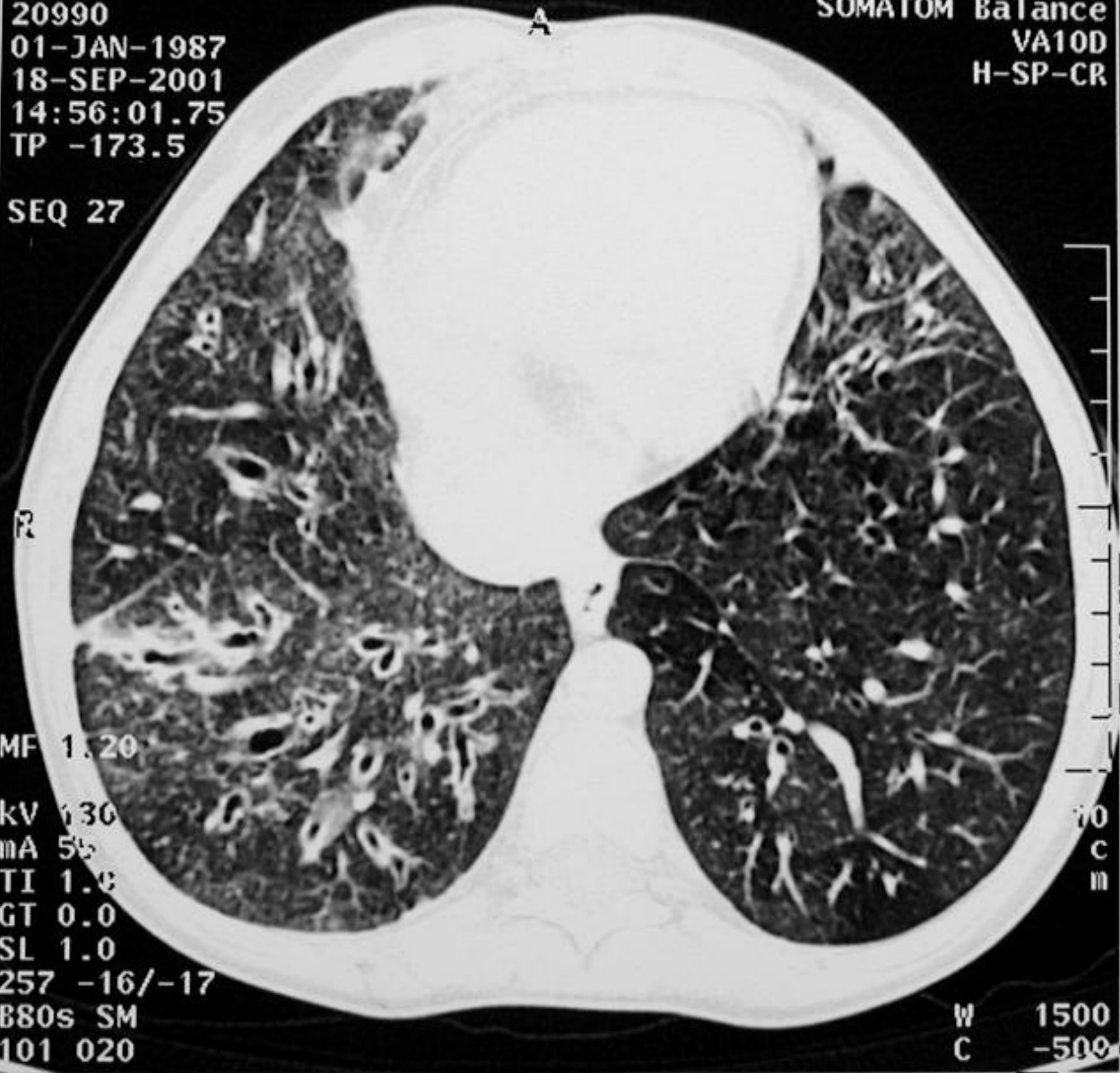257 -16/-17

B80s SM

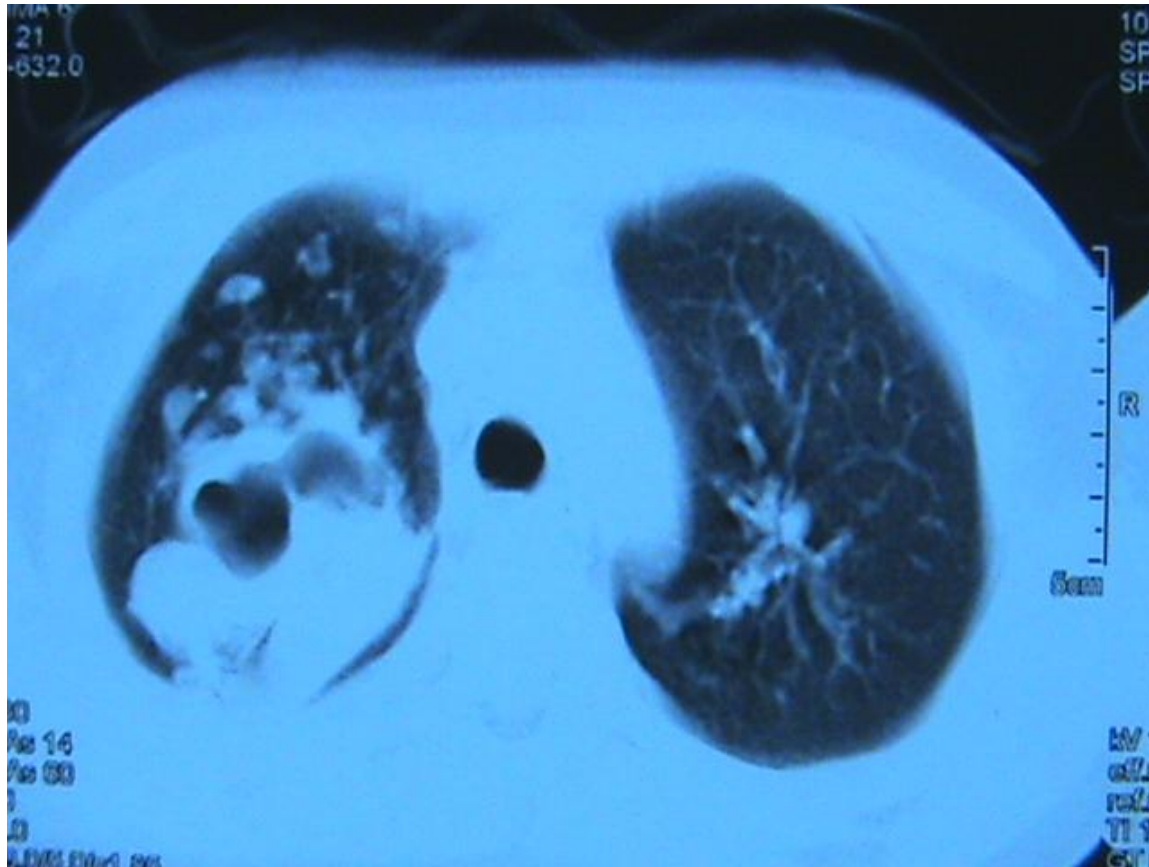
101 020

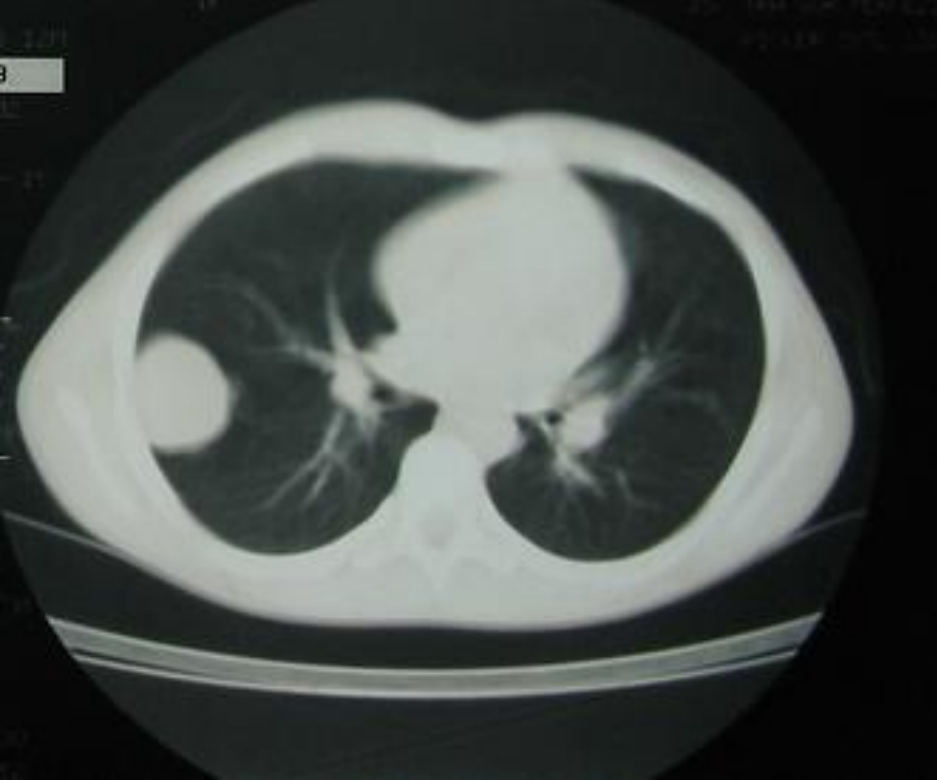W 1500

C -500

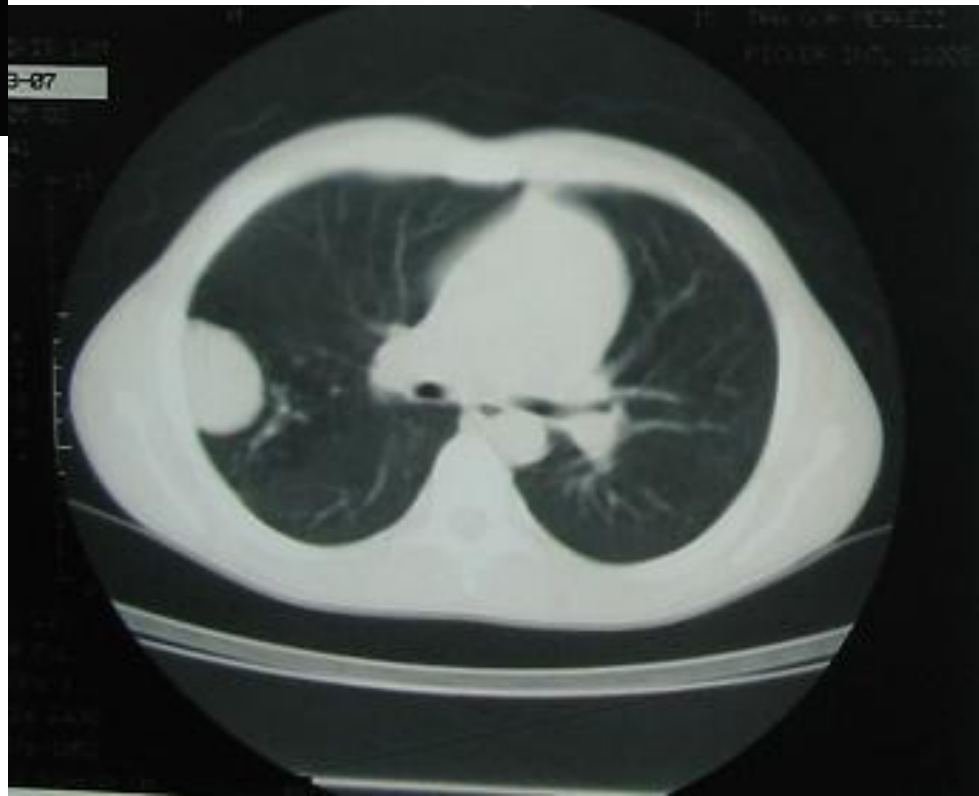


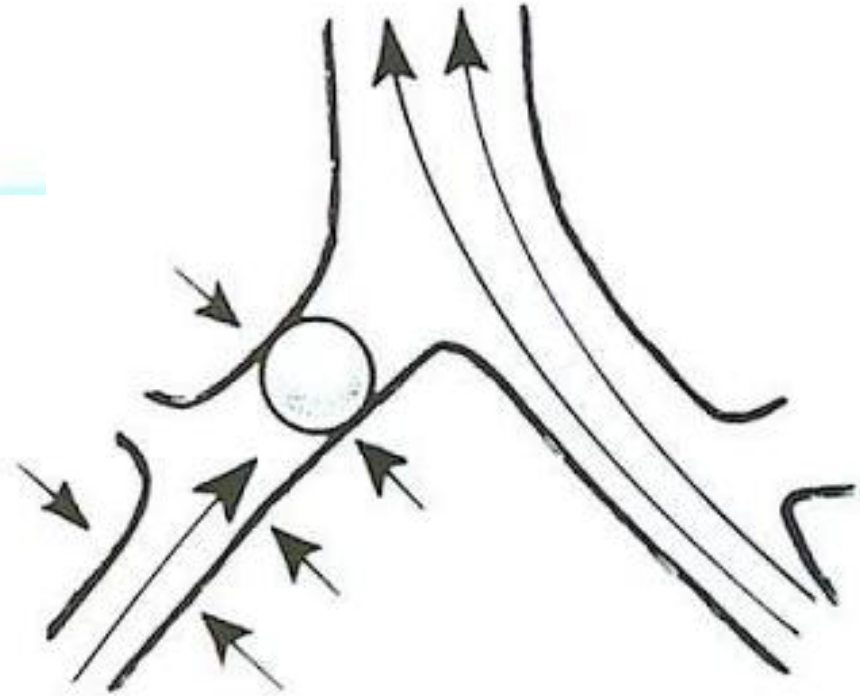
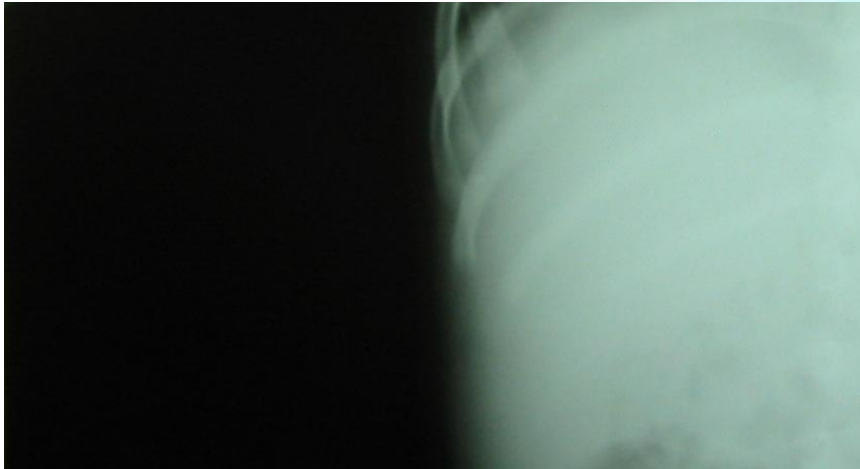
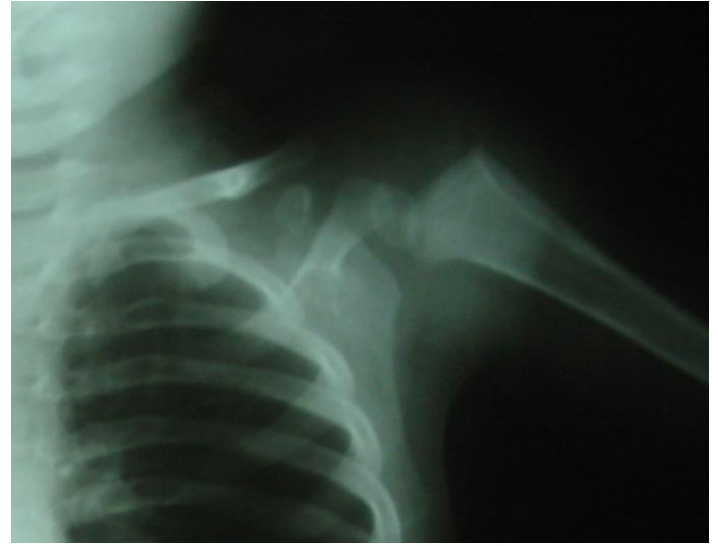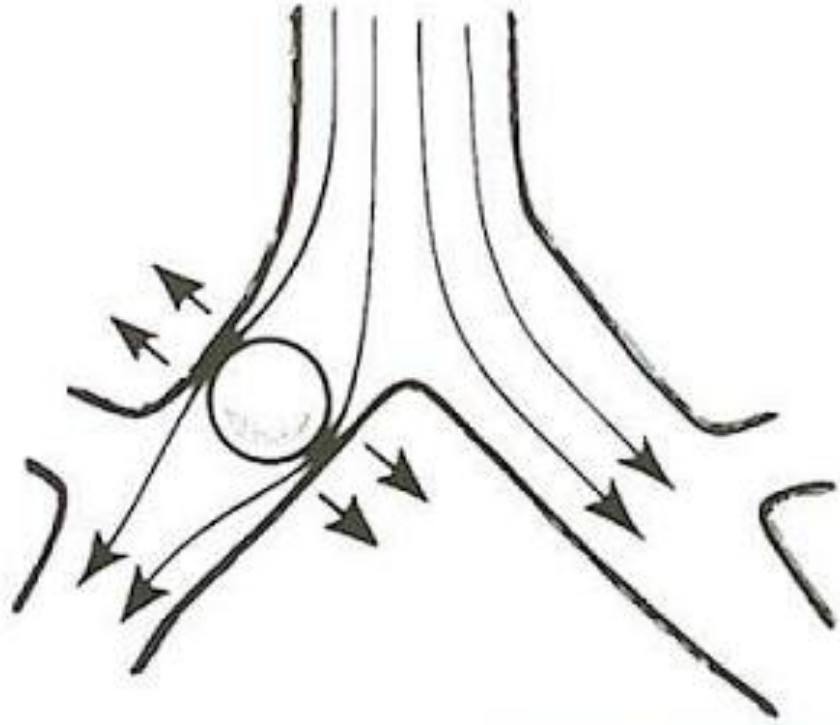
Invaziv aspergillozis



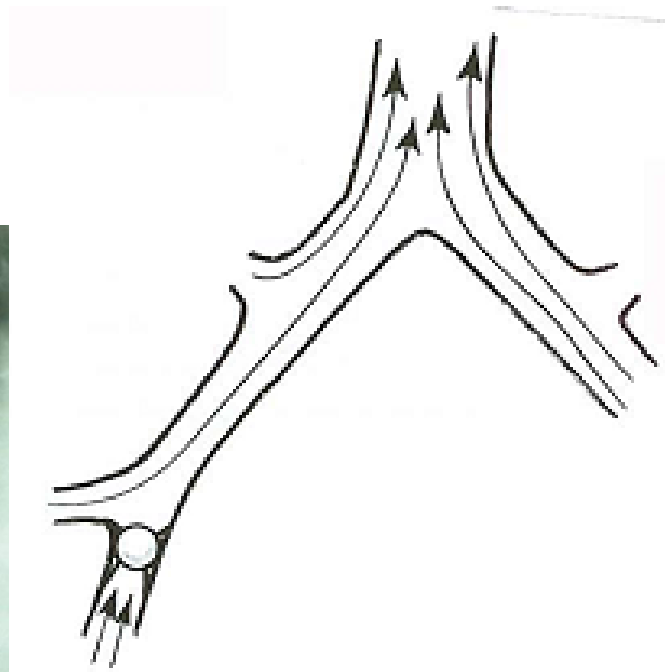
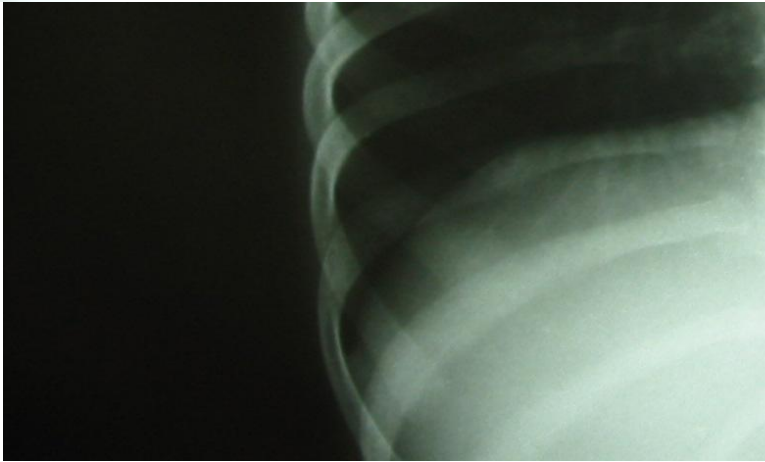
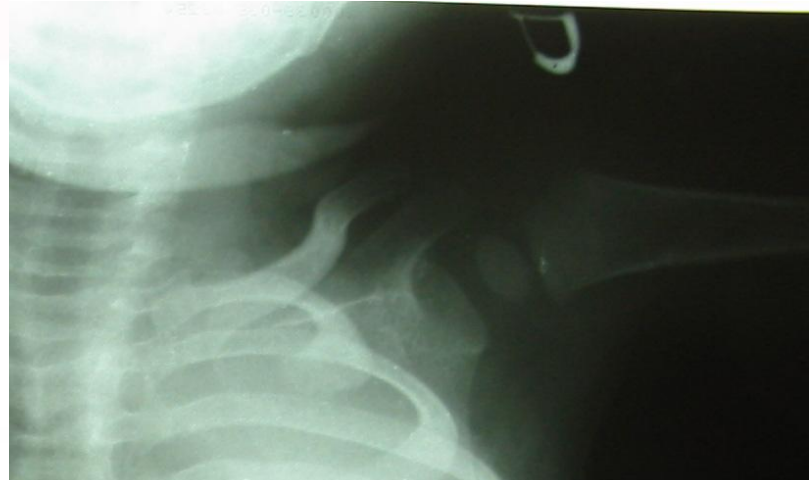
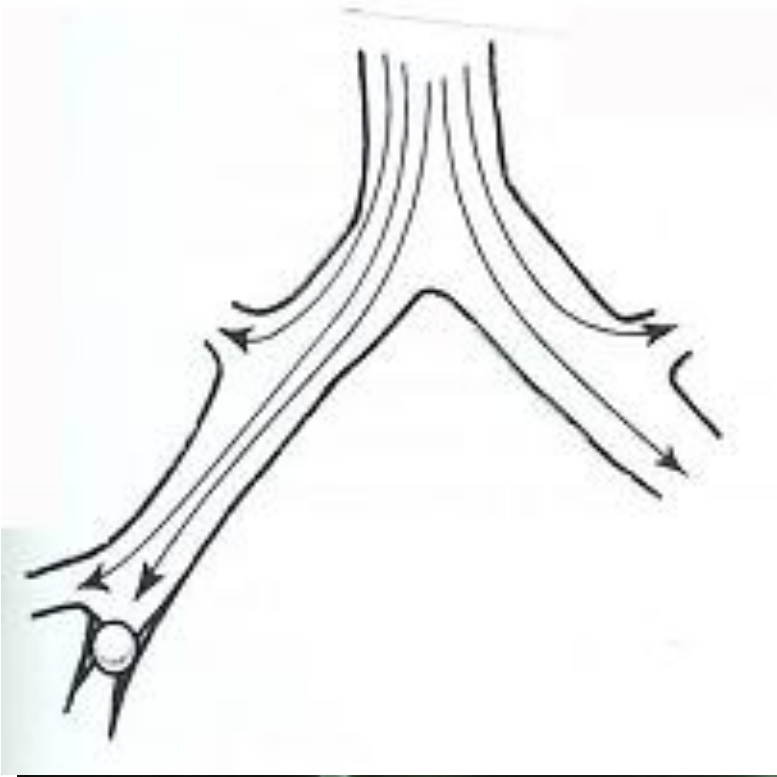


HİDATİK KİST



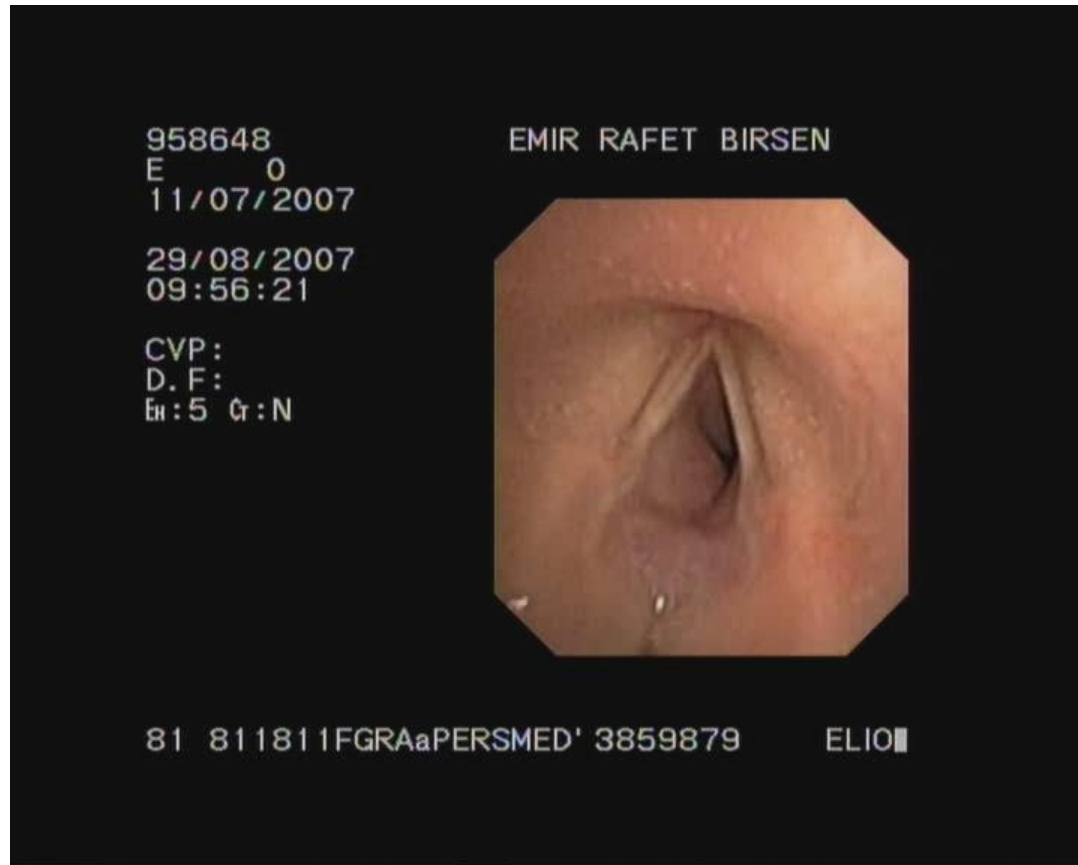


Yabancı cisim aspirasyo

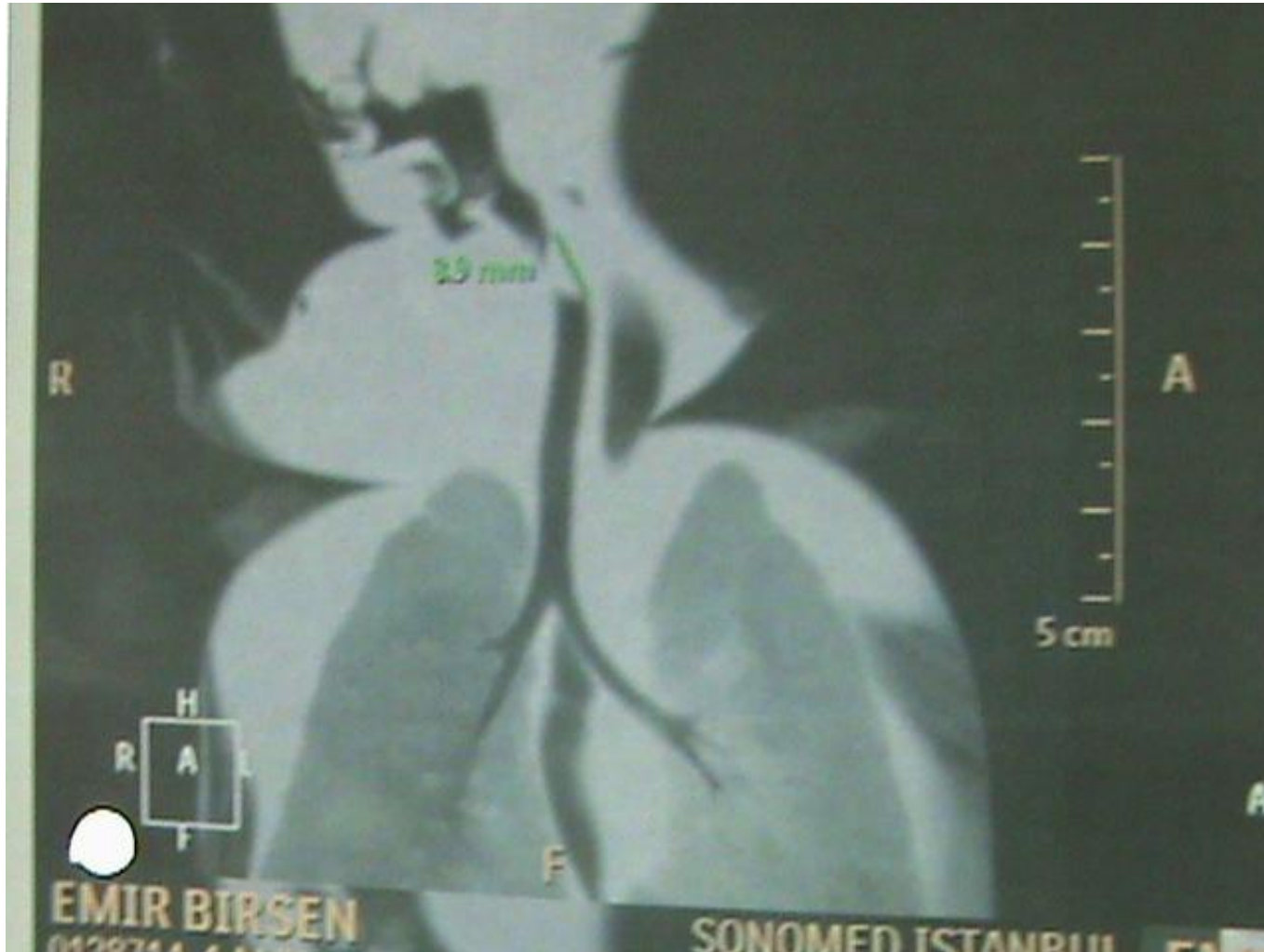


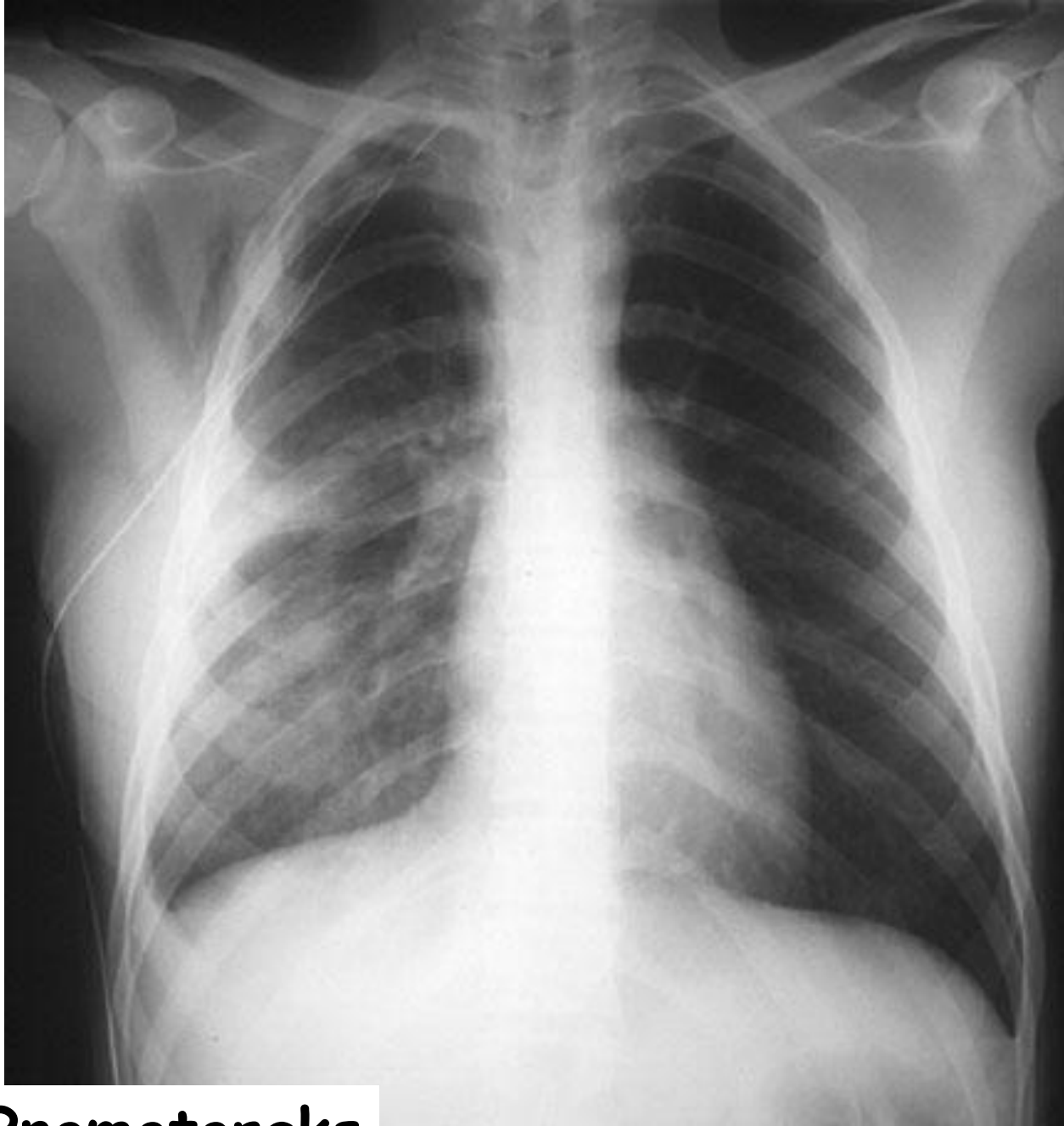Yabancı cisim aspirasyonu, Total atelektazi

Subglottik alanda kitle

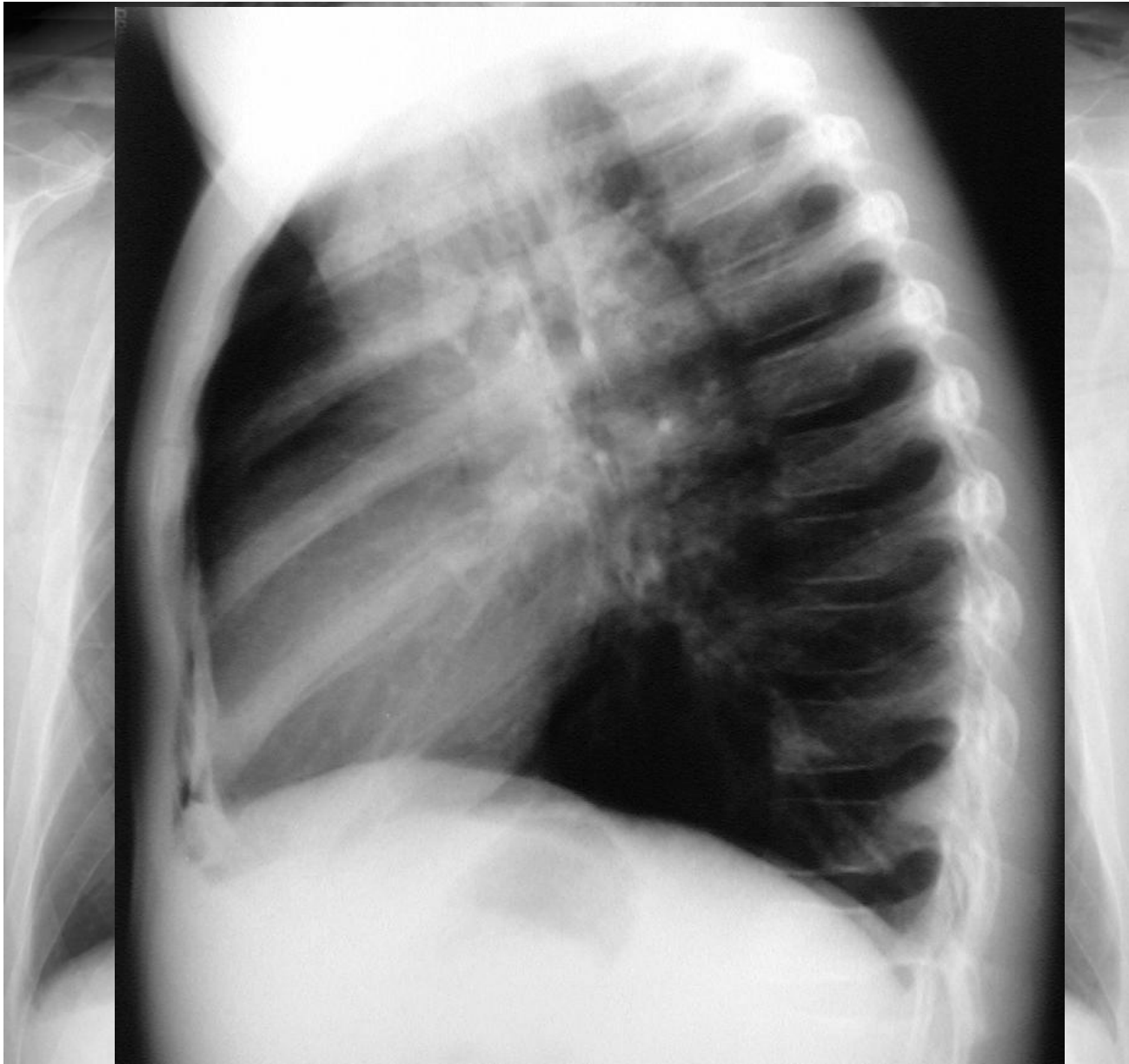

Subglottik alanda kitle

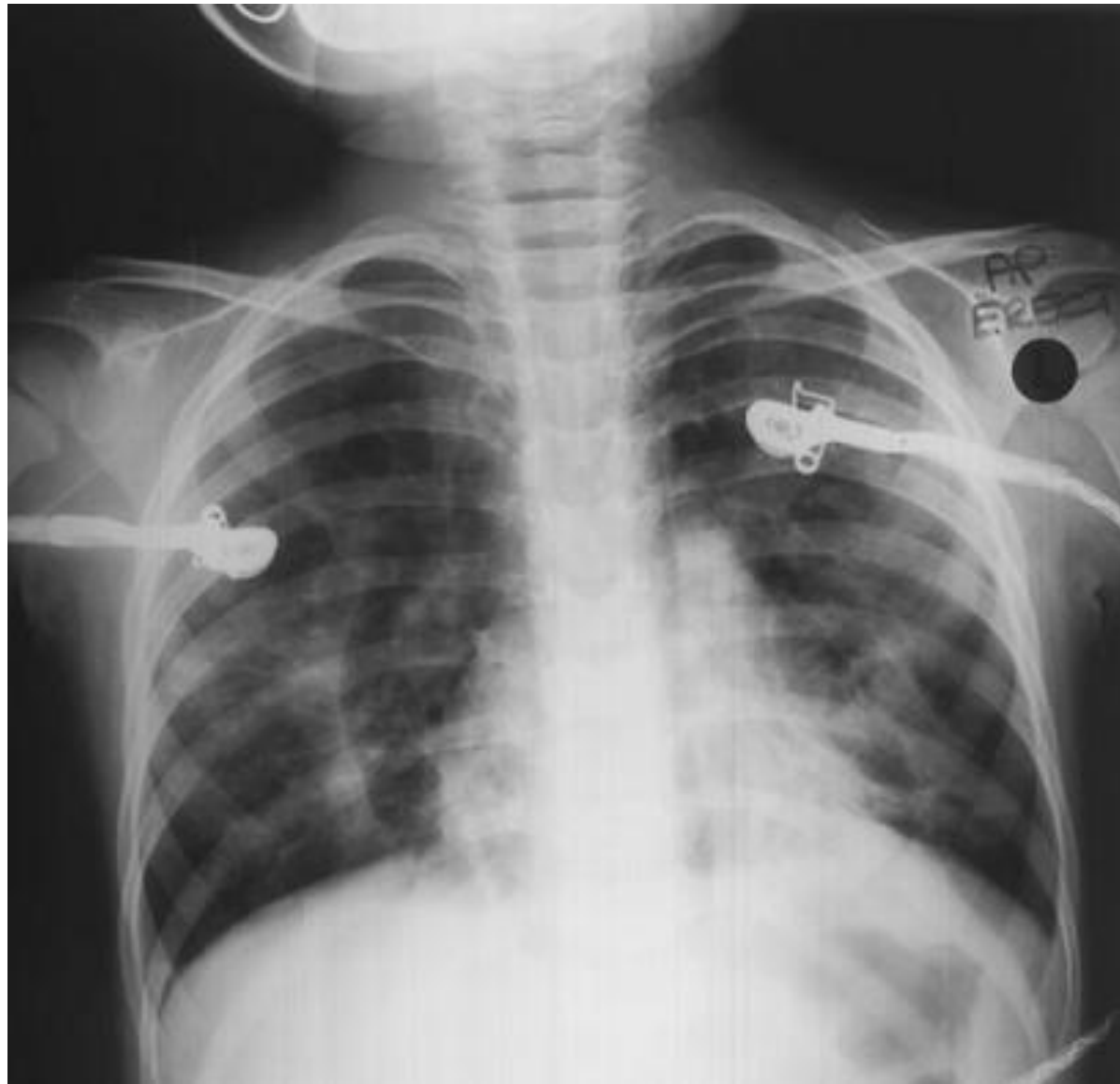



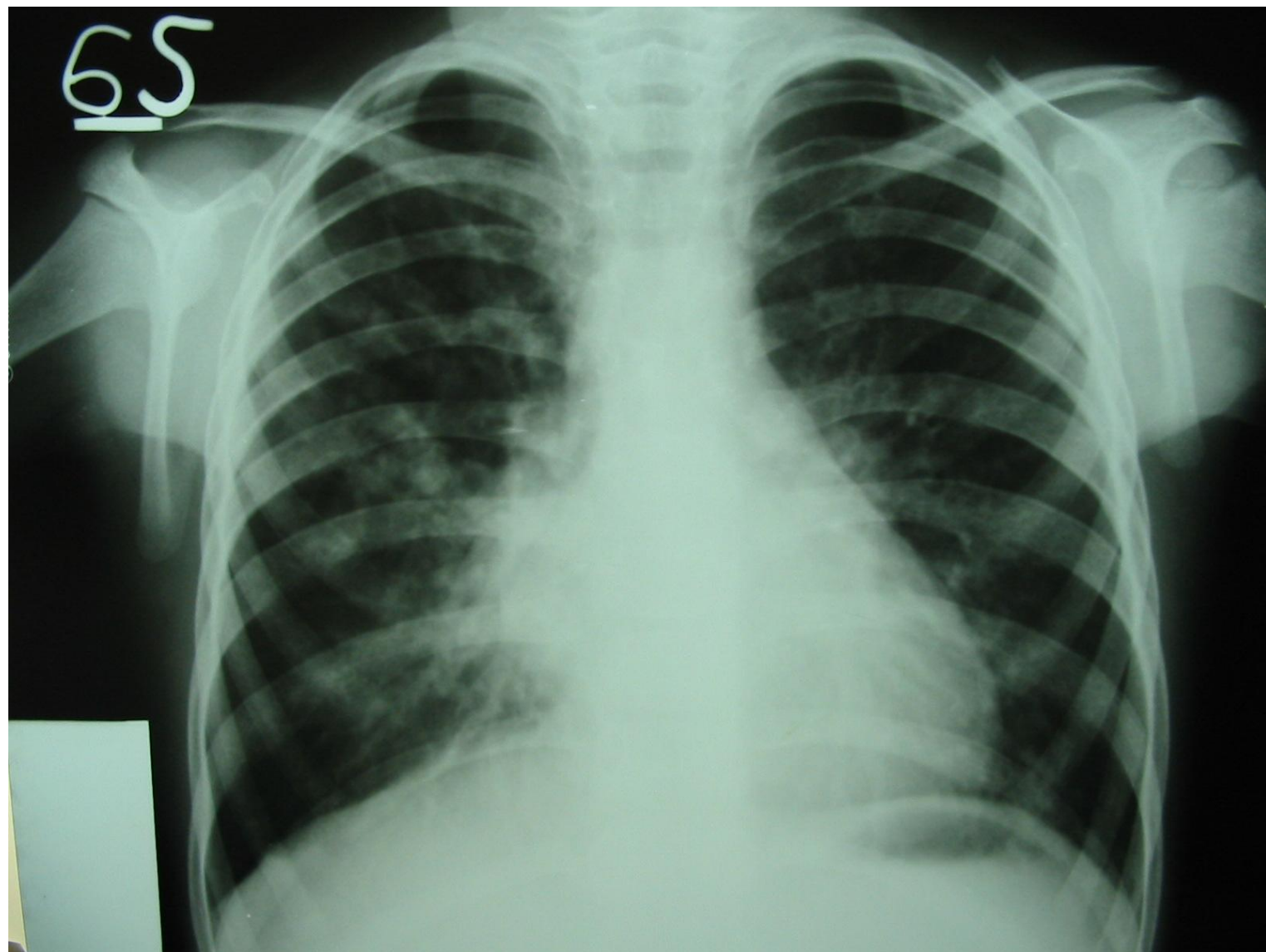
Pnomotoraks



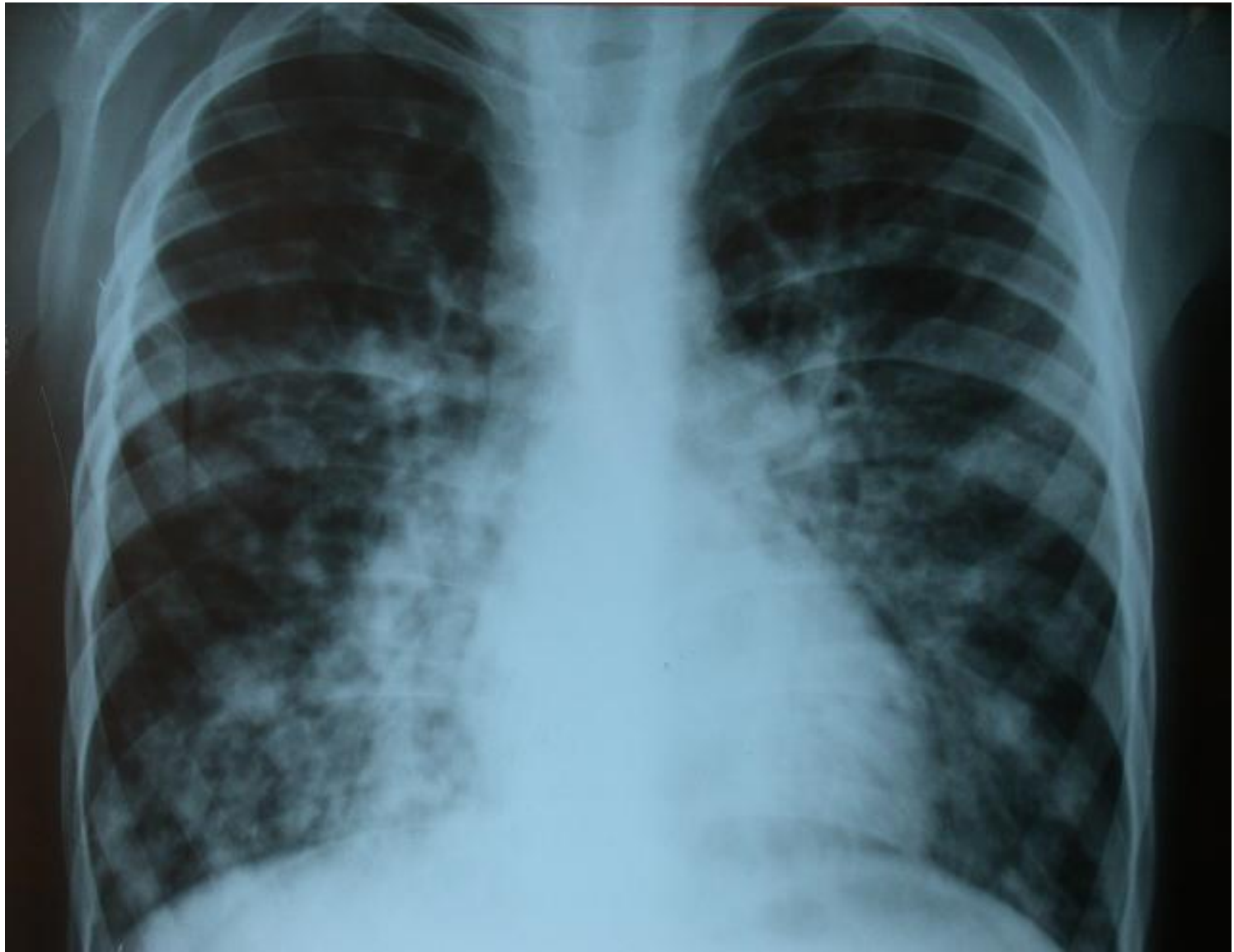Pnomomediastinum



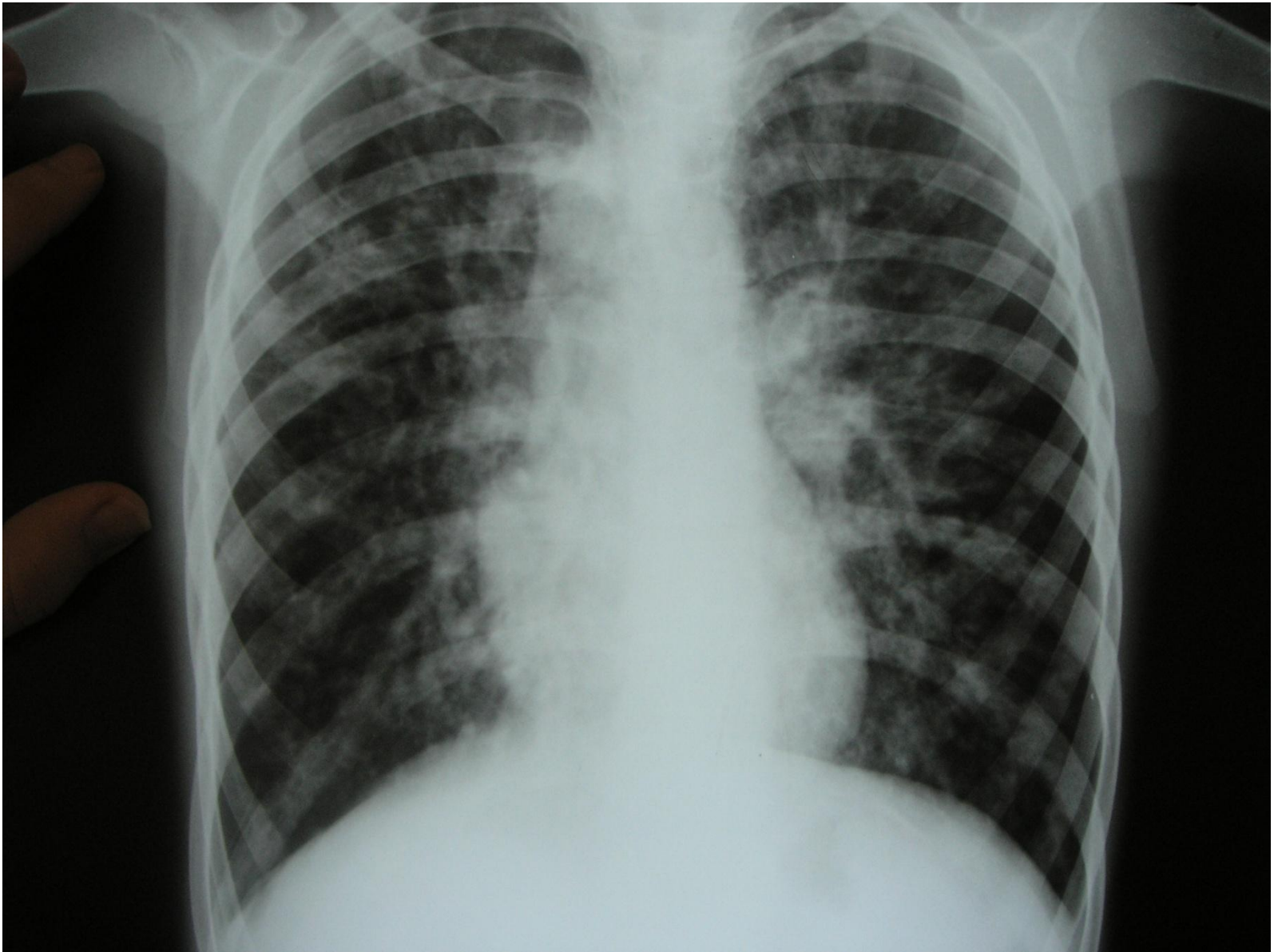
Pnomomediastinum

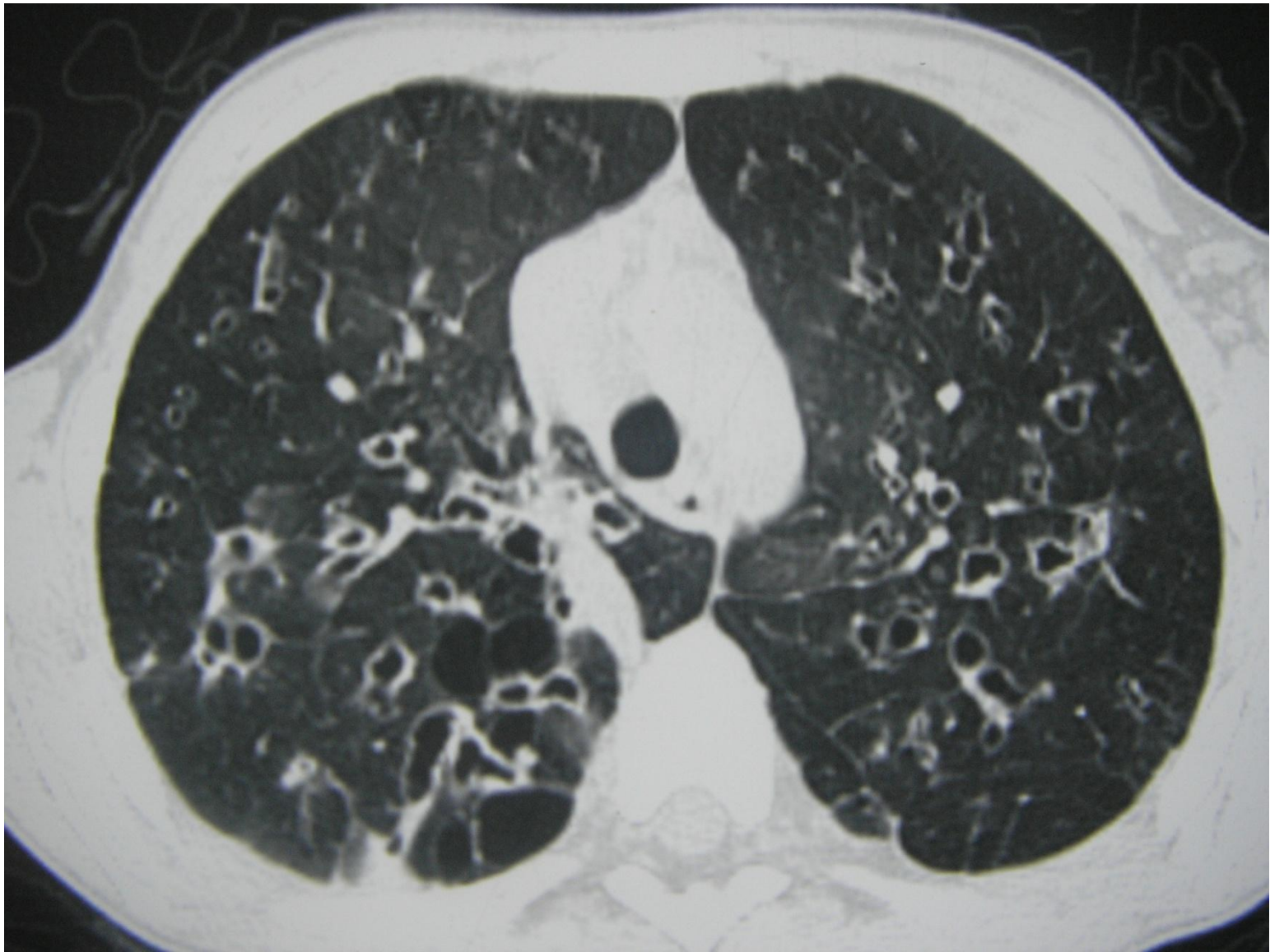


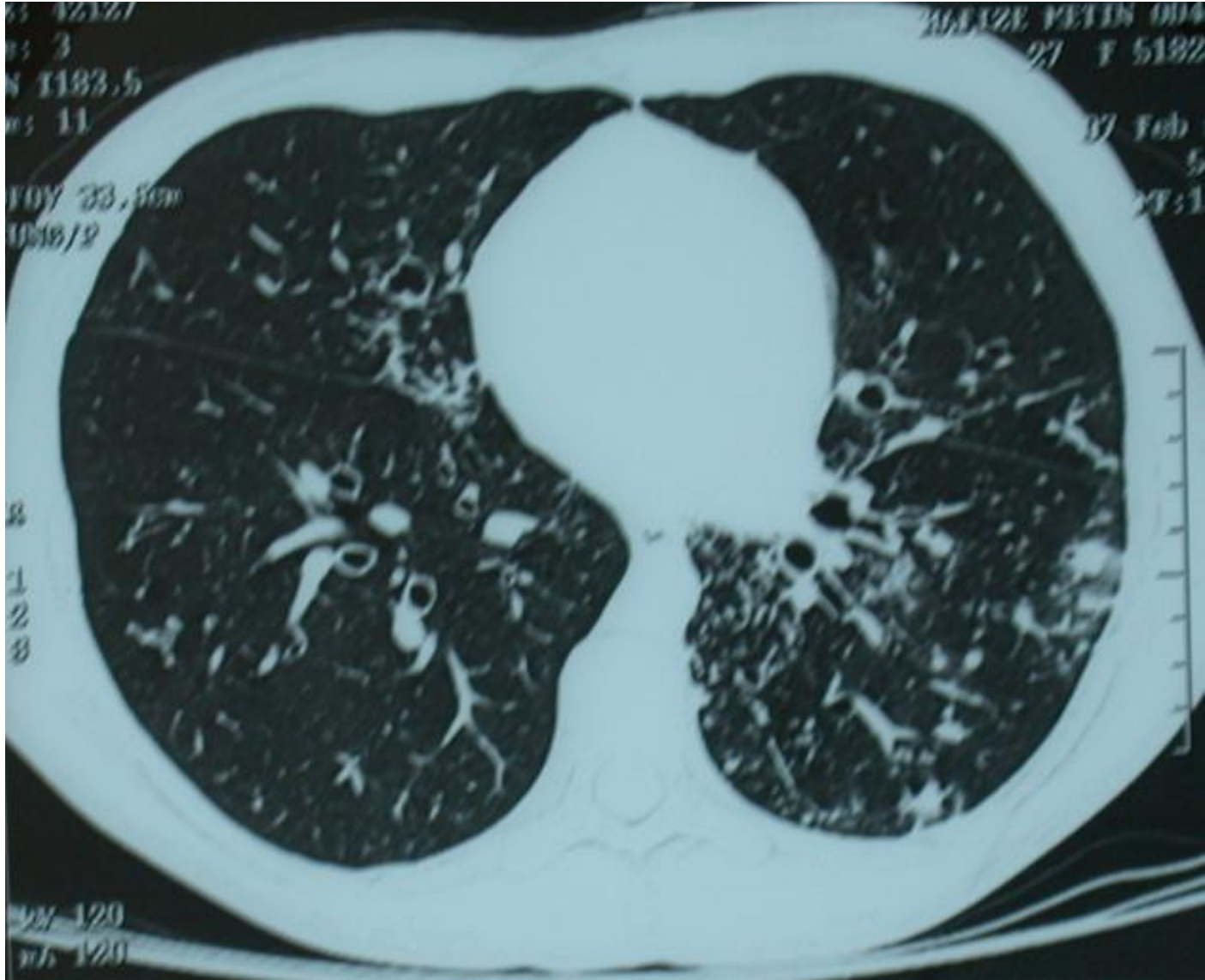Kistik Fibrosis



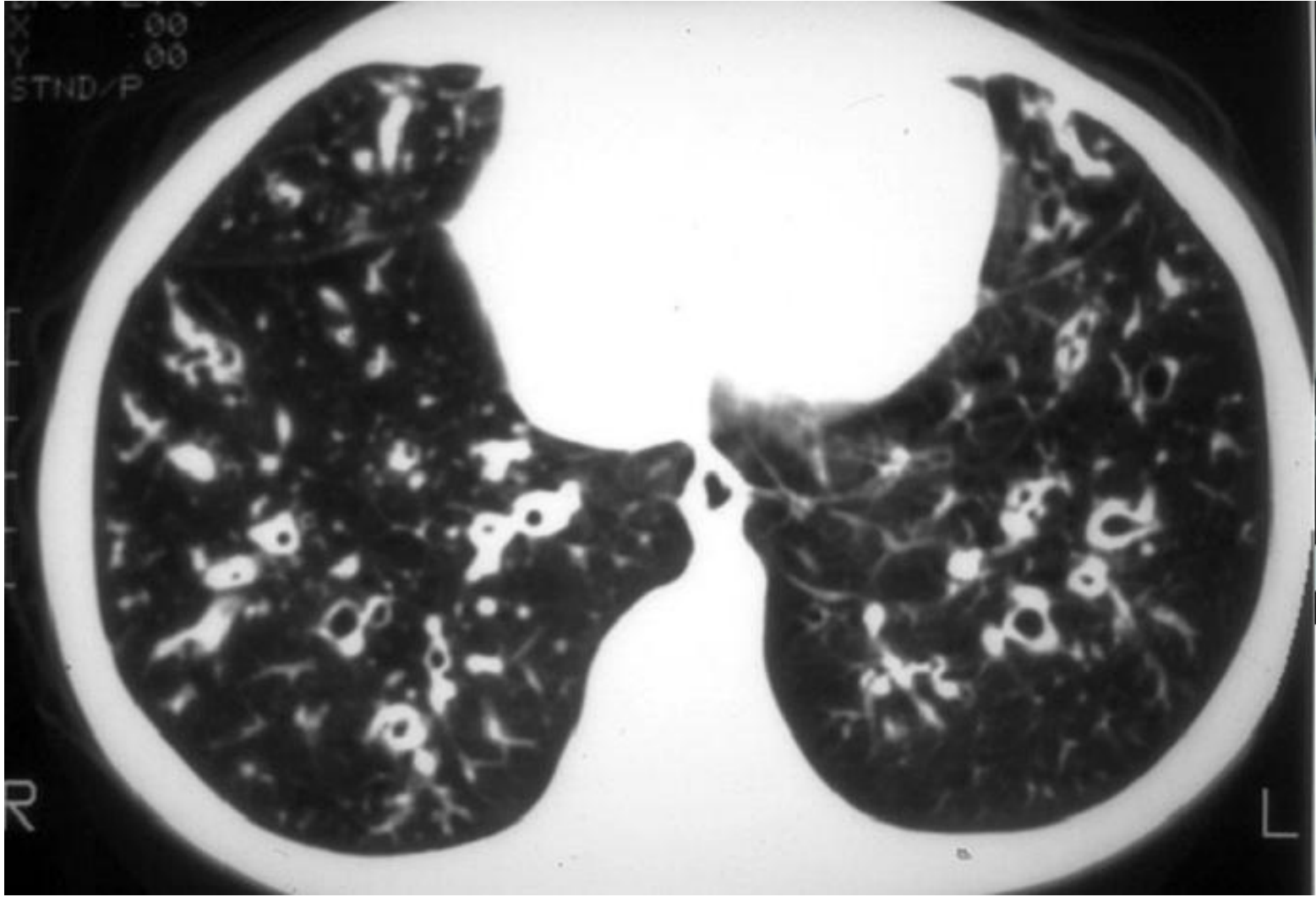
Kistik Fibrosis





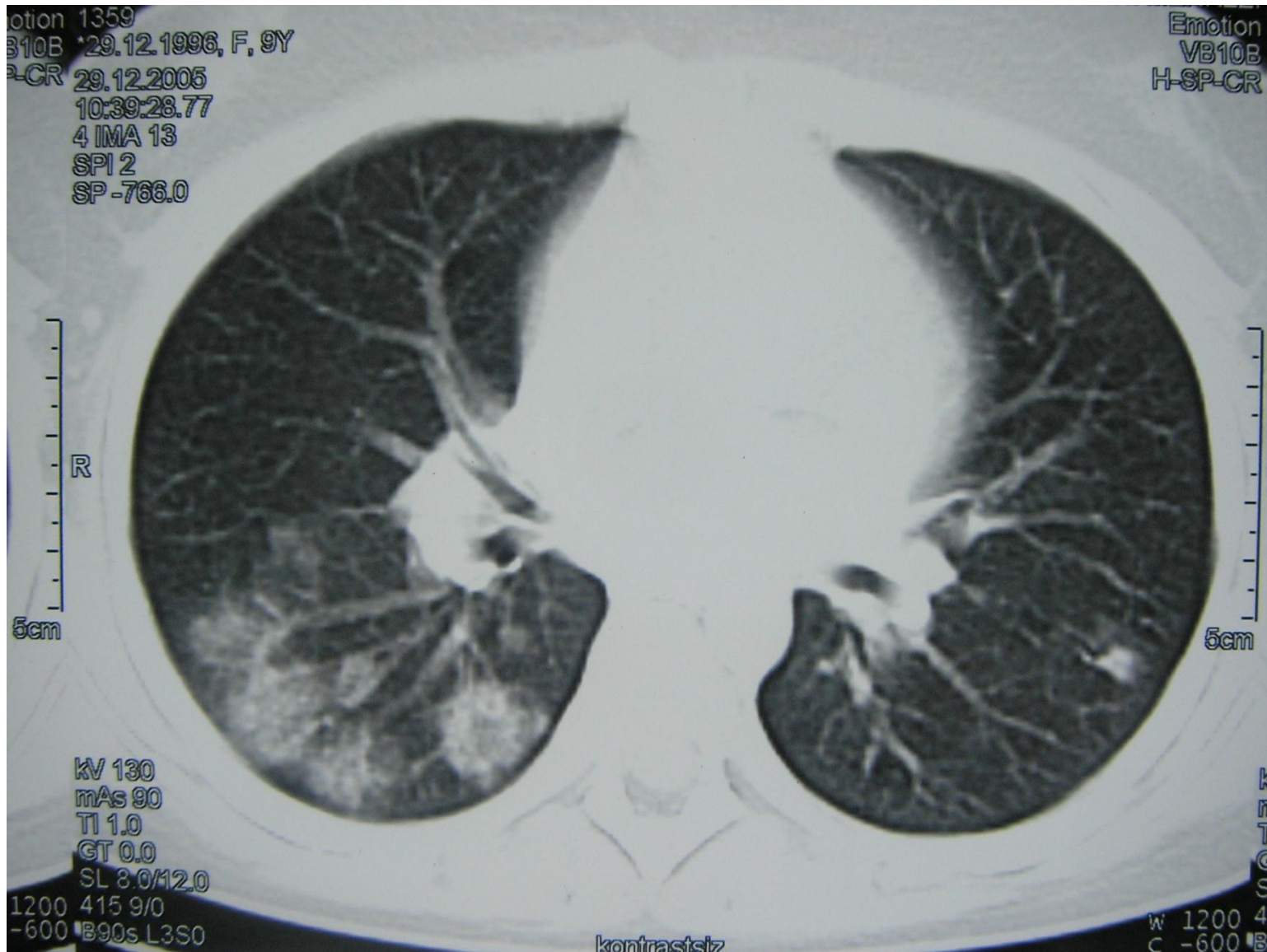


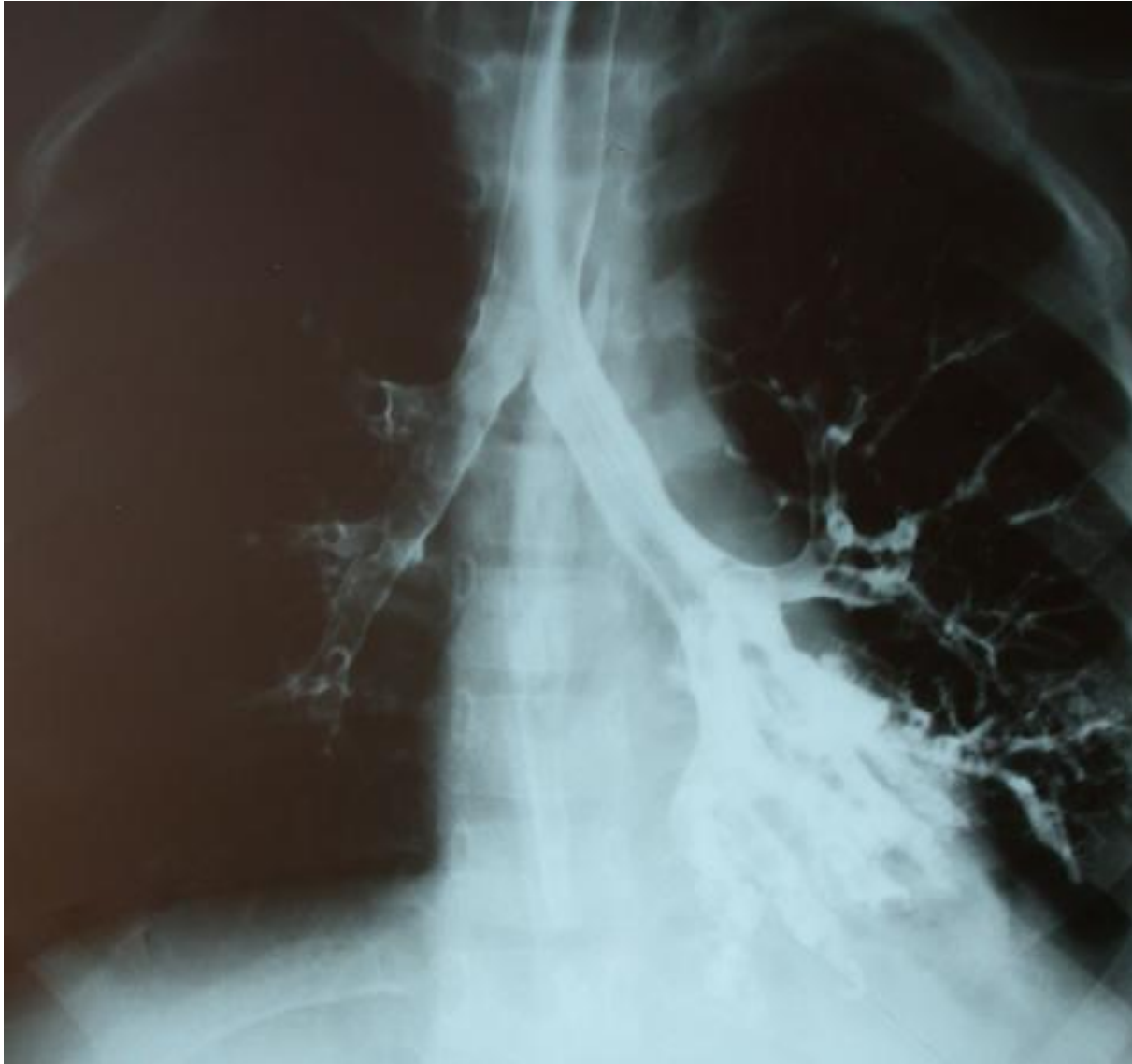Kistik fibrozis bronşiektazi



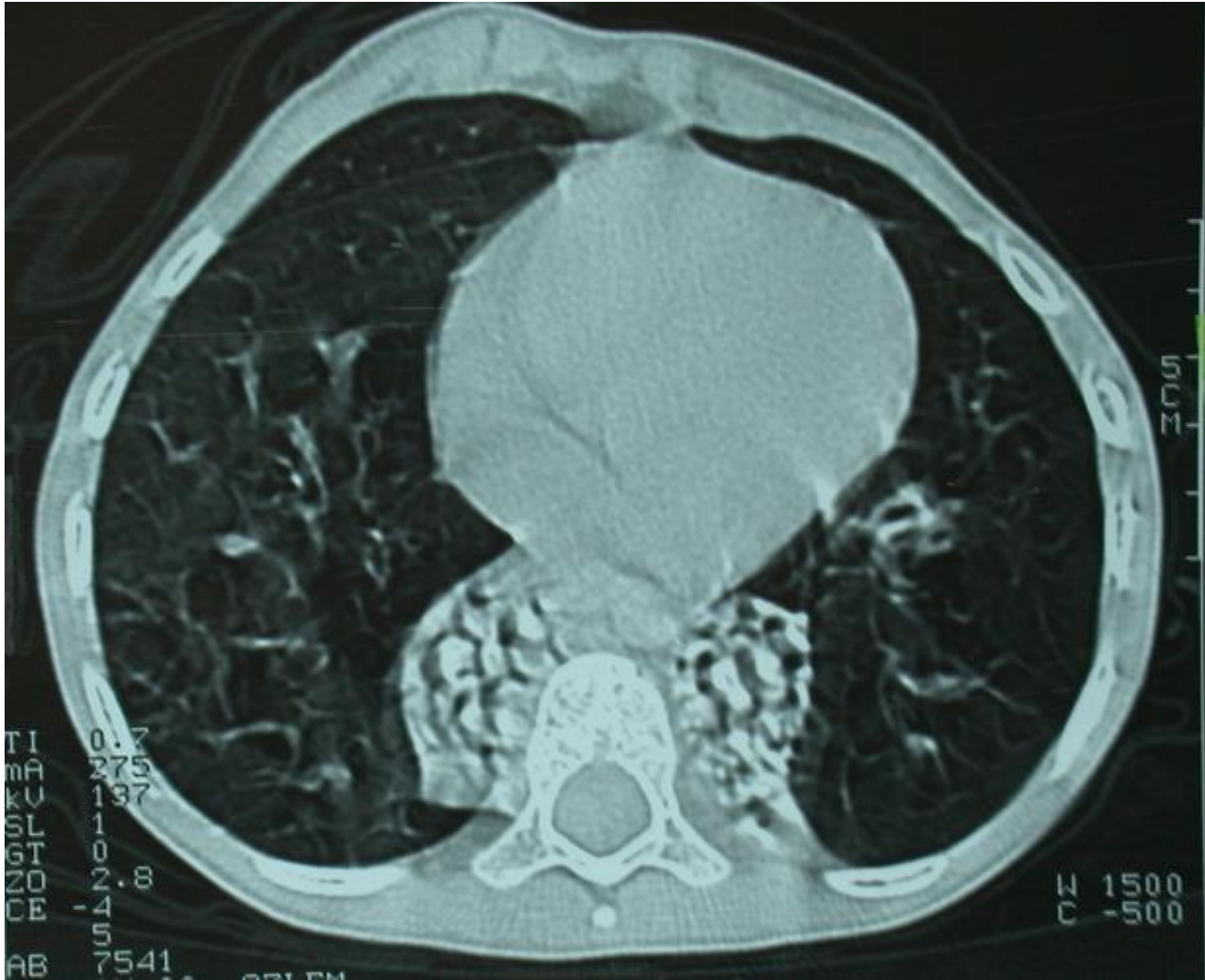
ÖK Kistik Fibrozis 27 yaş erkek hasta

Kistik Fibrozis-ABPA

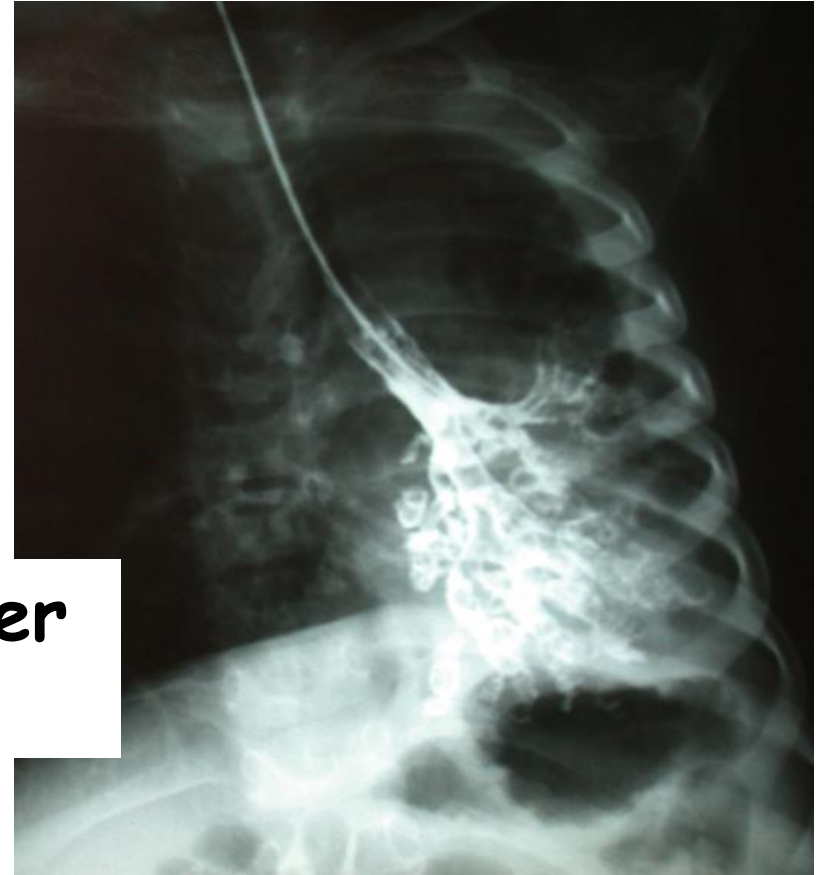
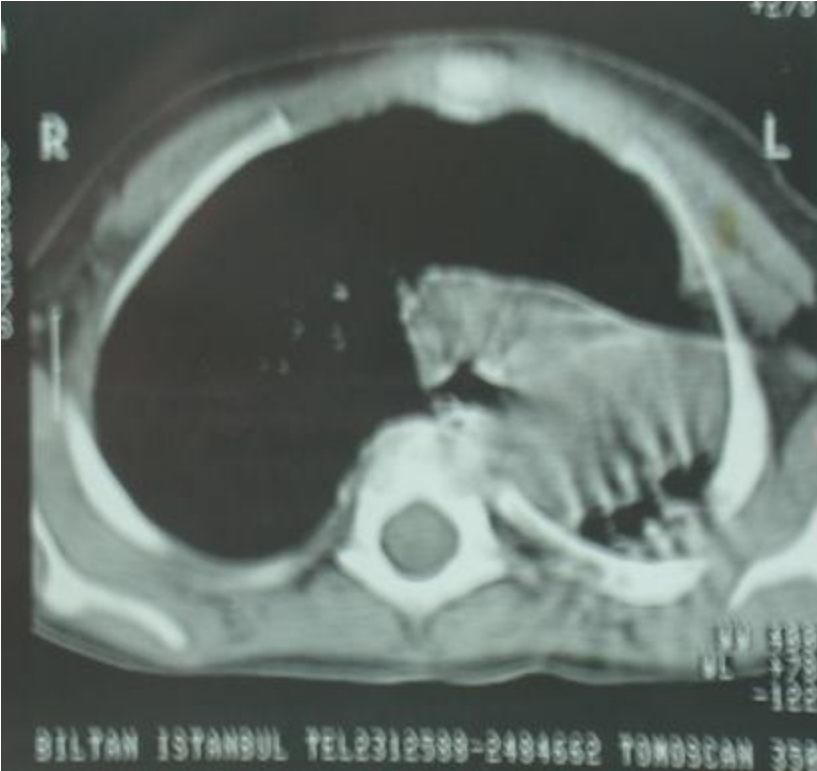



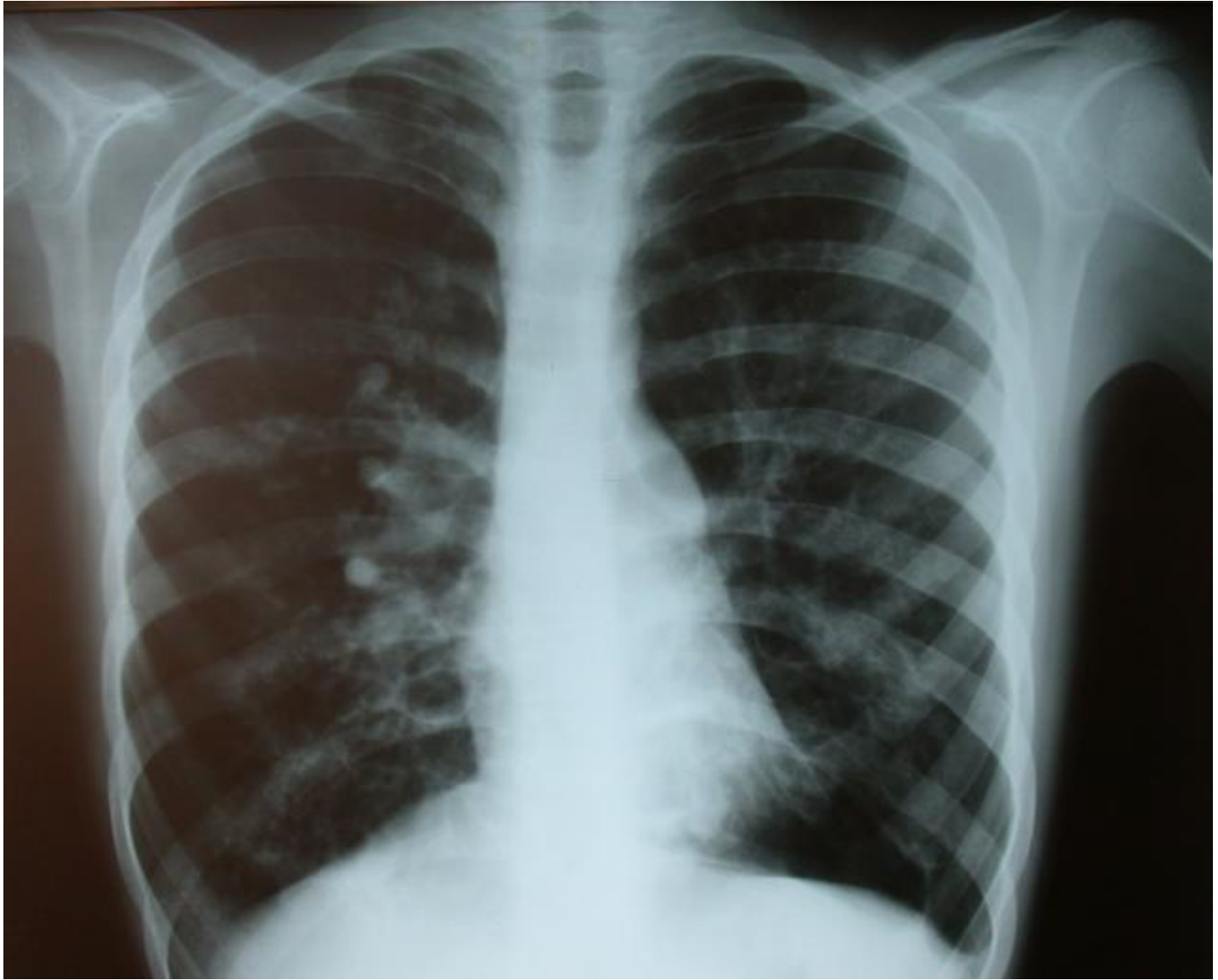
CD, Sol alt lob bronşiektazi (Opere)



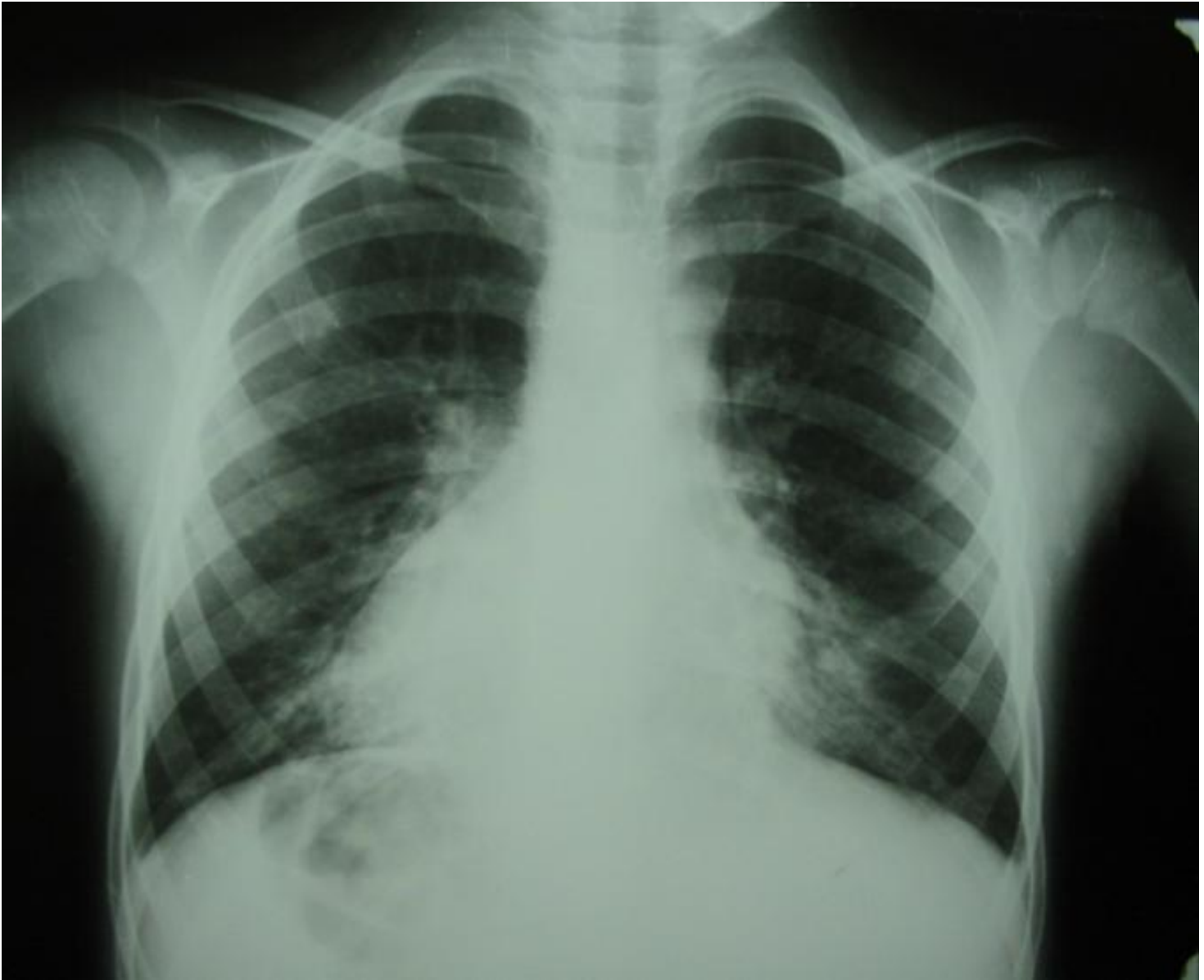**BK 6 yaş kız hasta ,
1 yaşında kızamık sonrası bronşiektazi**



**Solda harab olmuş akciğer
Bronkografi**

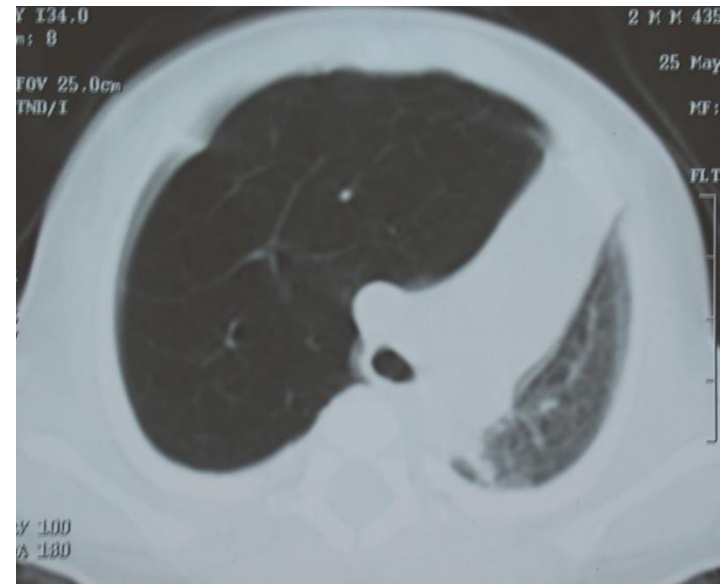
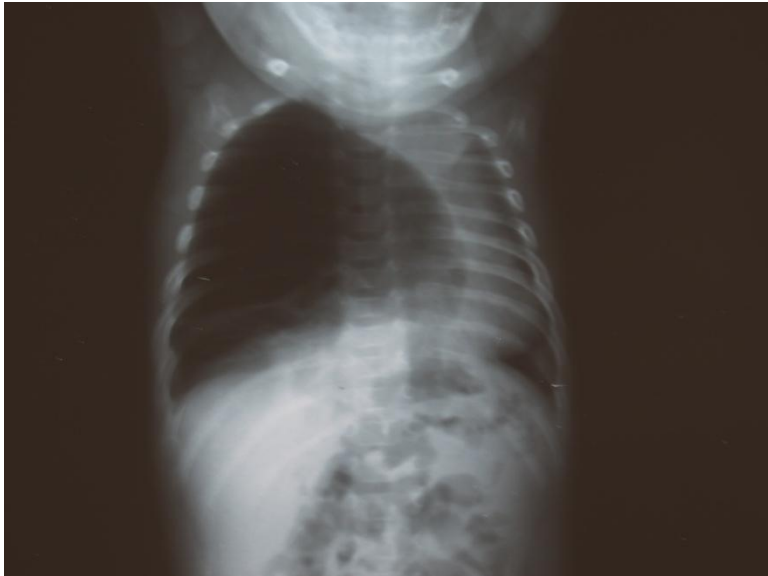

AE 20 yaş kız hasta Bronşiektazi etyoloji?

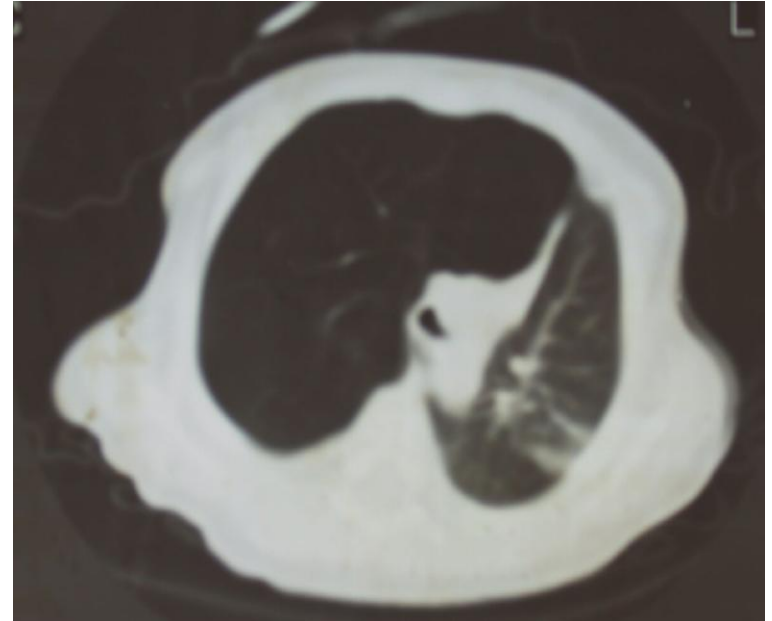
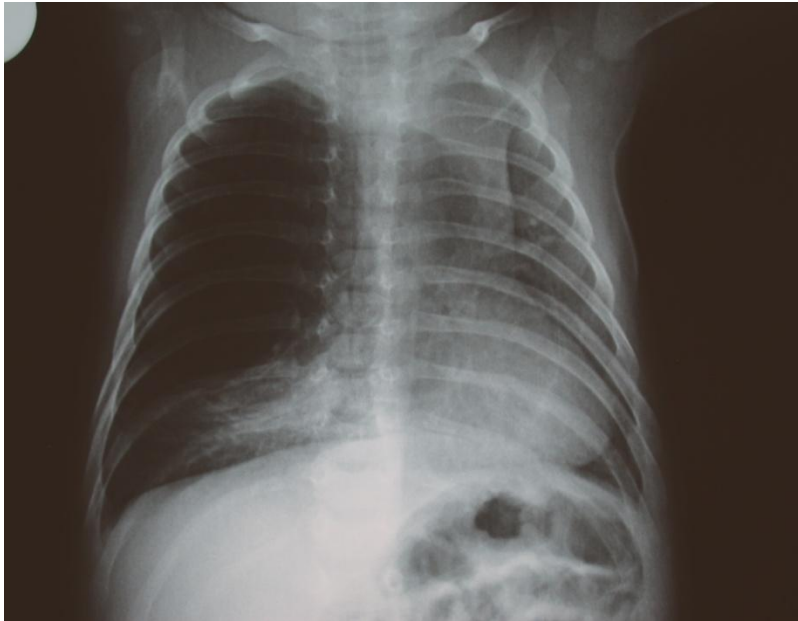


Kartaganer

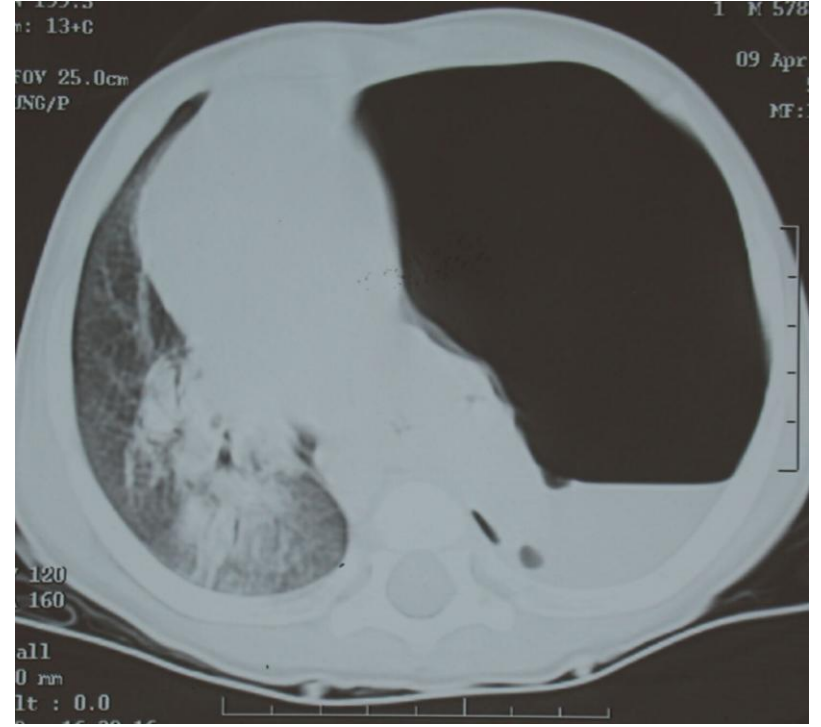
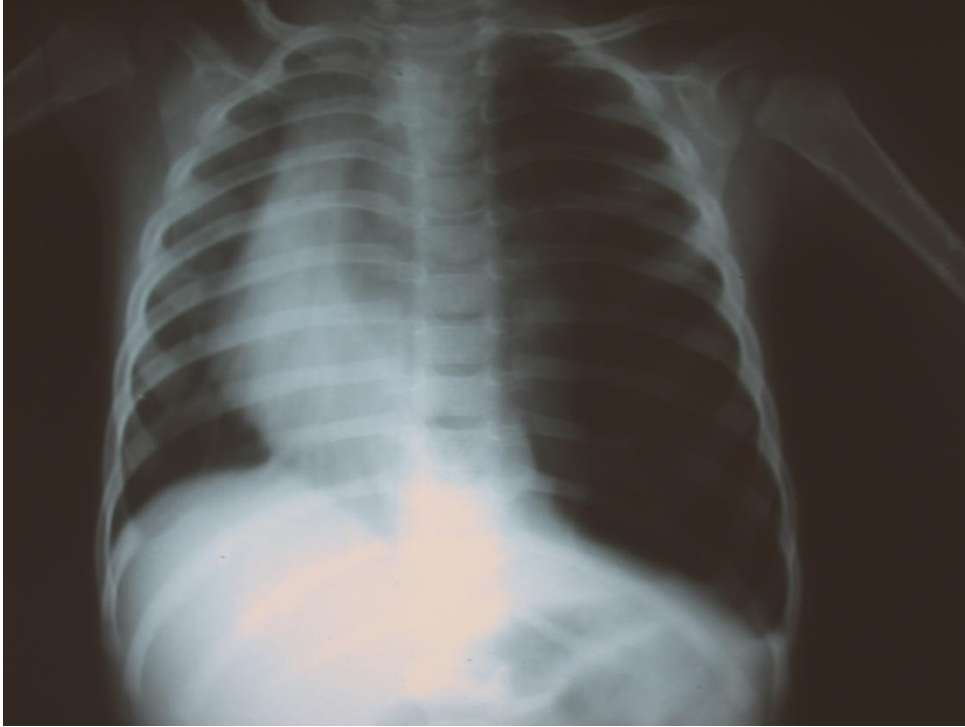Konjenital Lober Amfizem

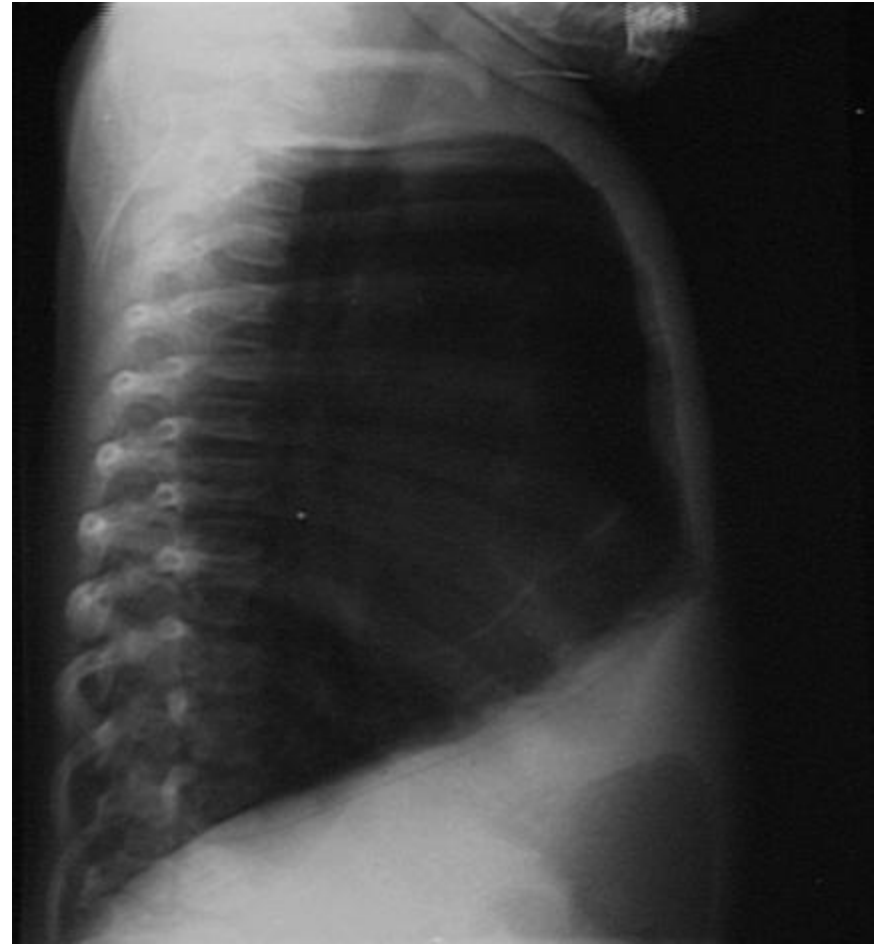
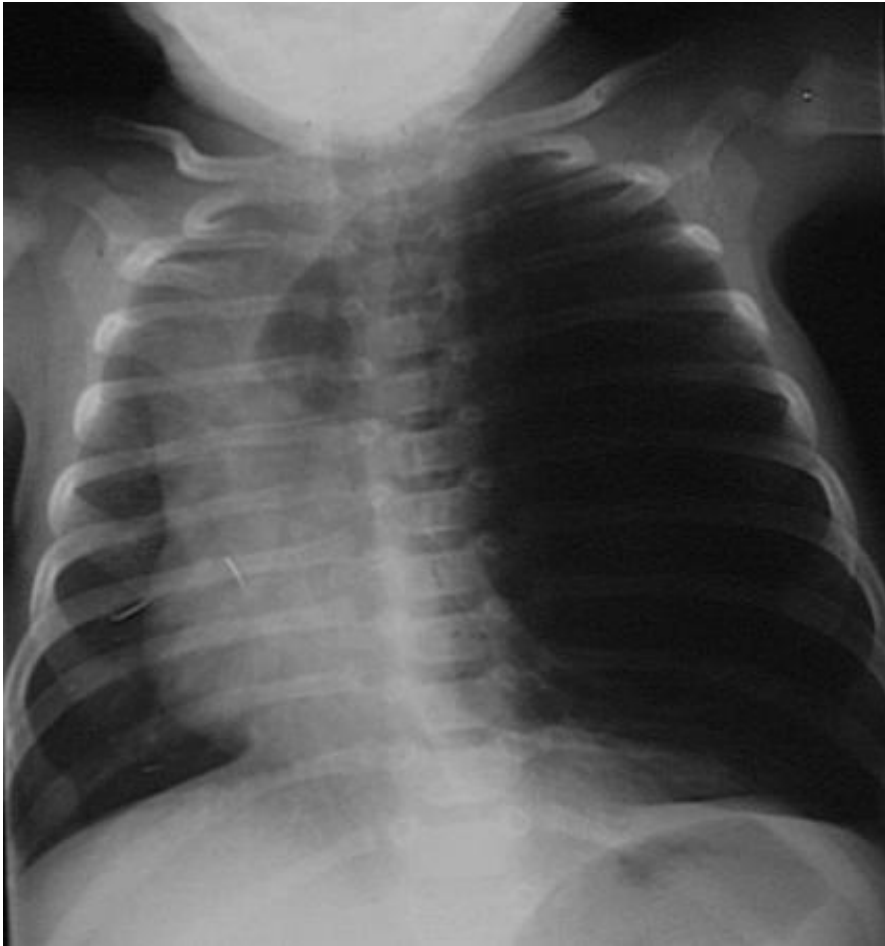

Konjenital Lober Amfizem

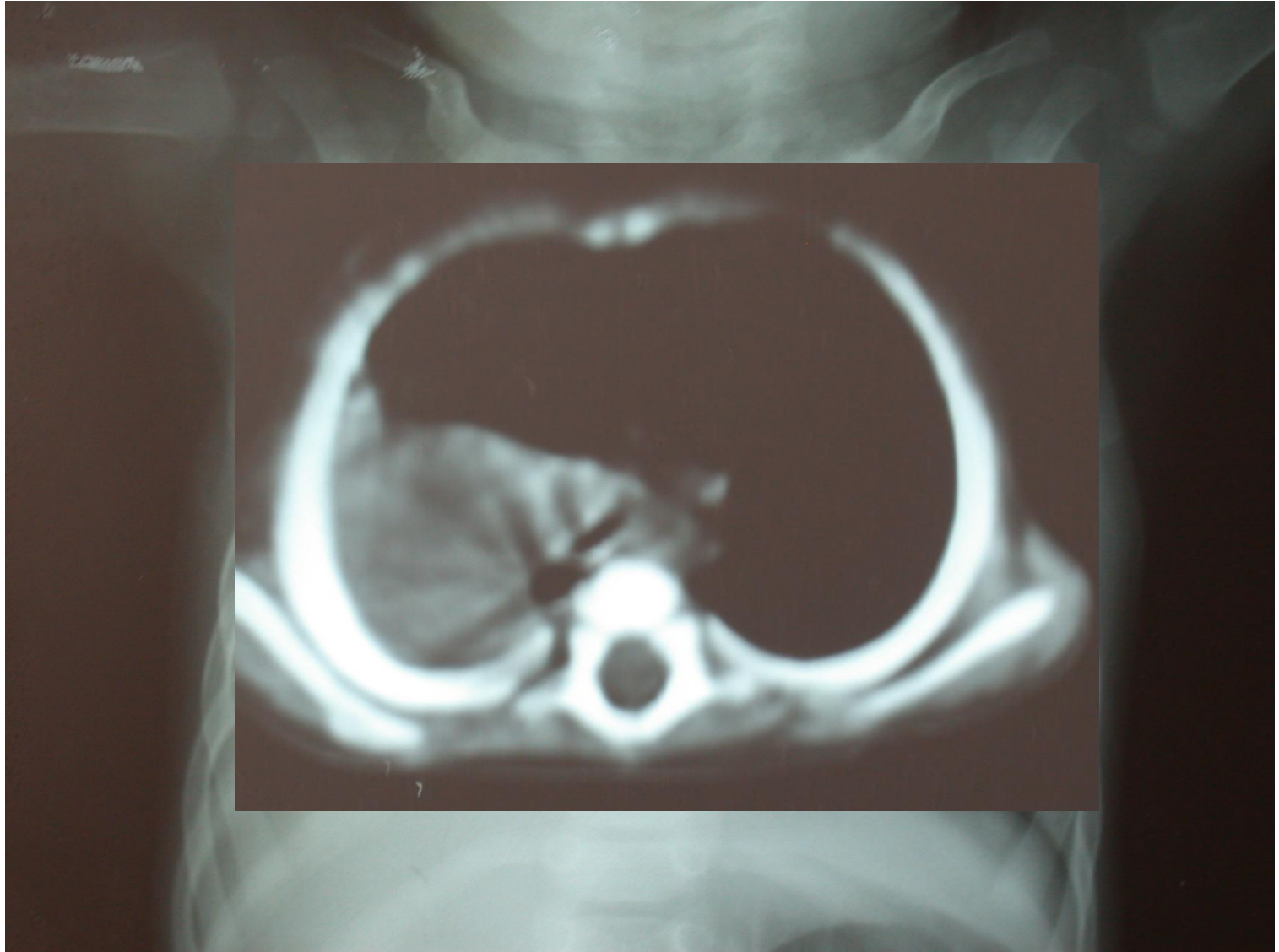


Tansiyon Pnömotoraks



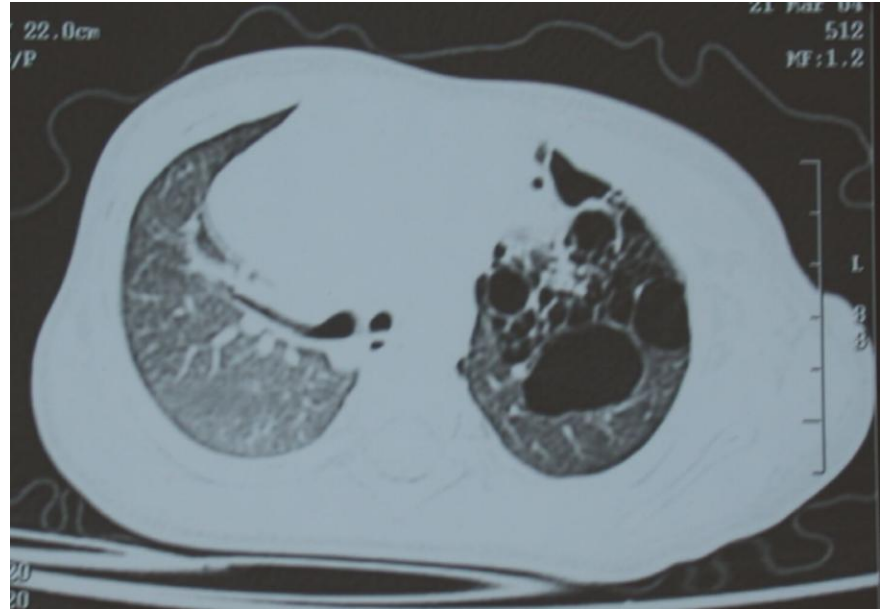
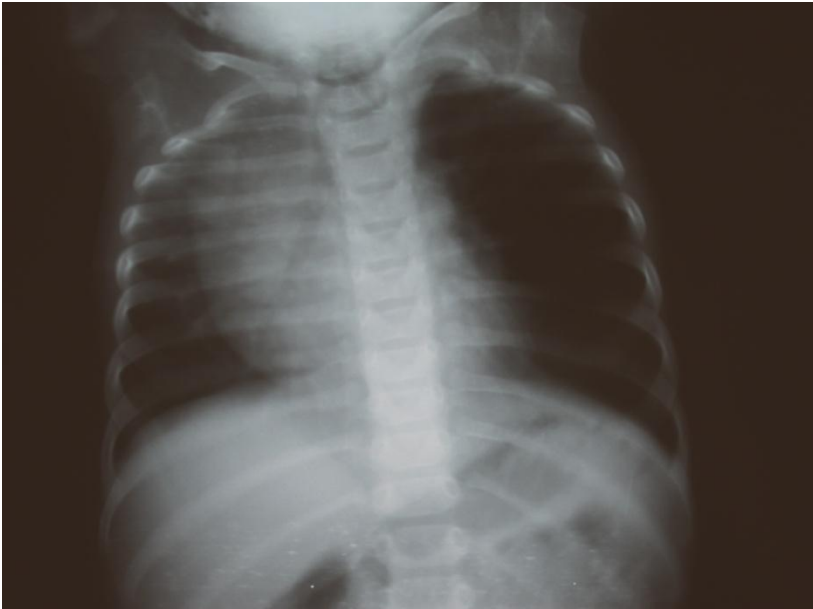


Konjenital lobar amfizem

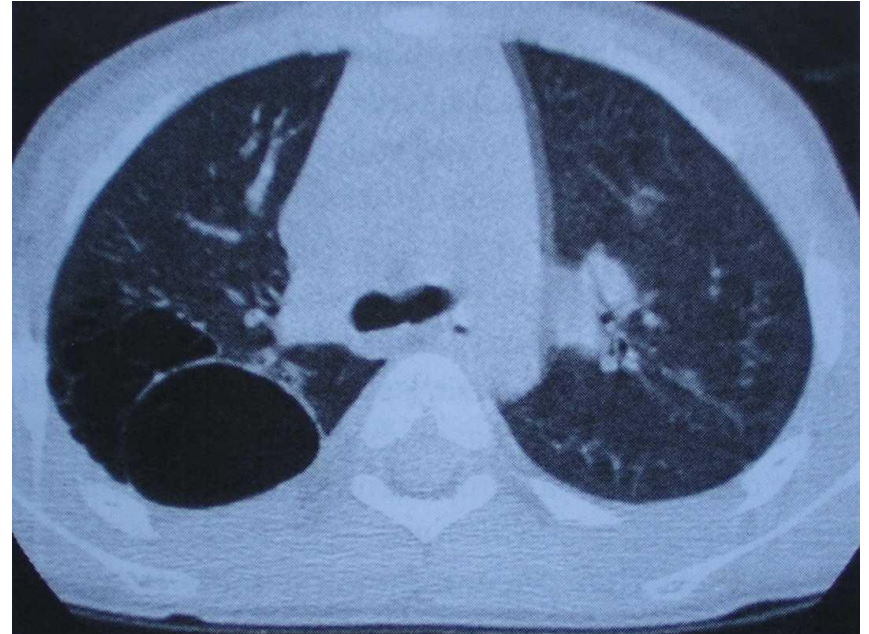
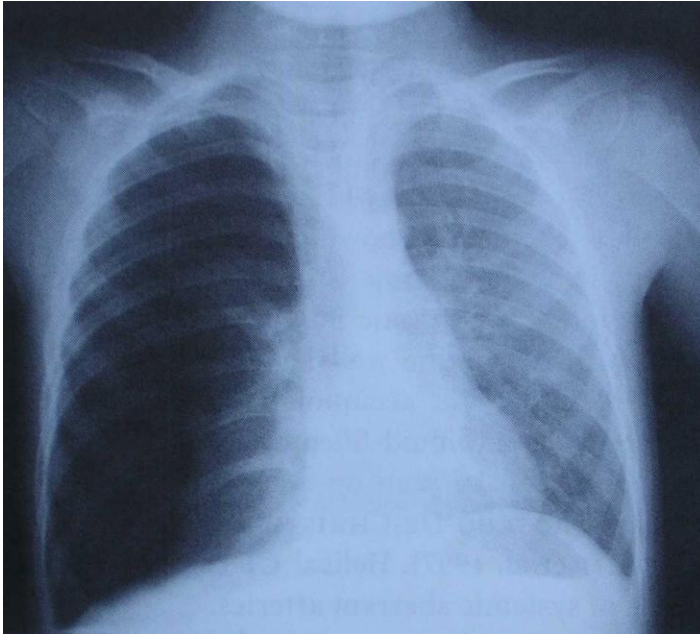


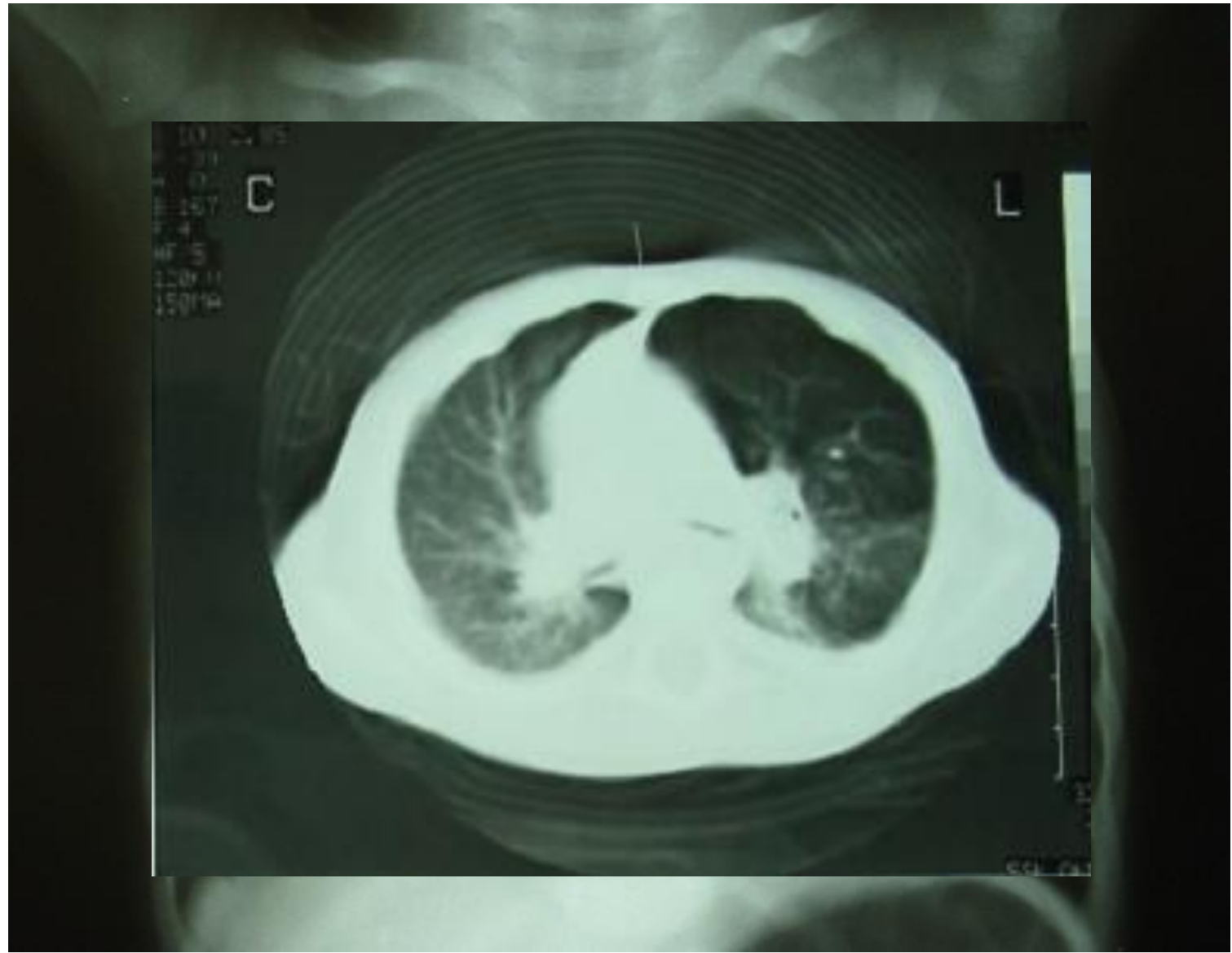Sağ akciğerde agenezi

Konjenital Kistik Adenomatoid Malformasyon

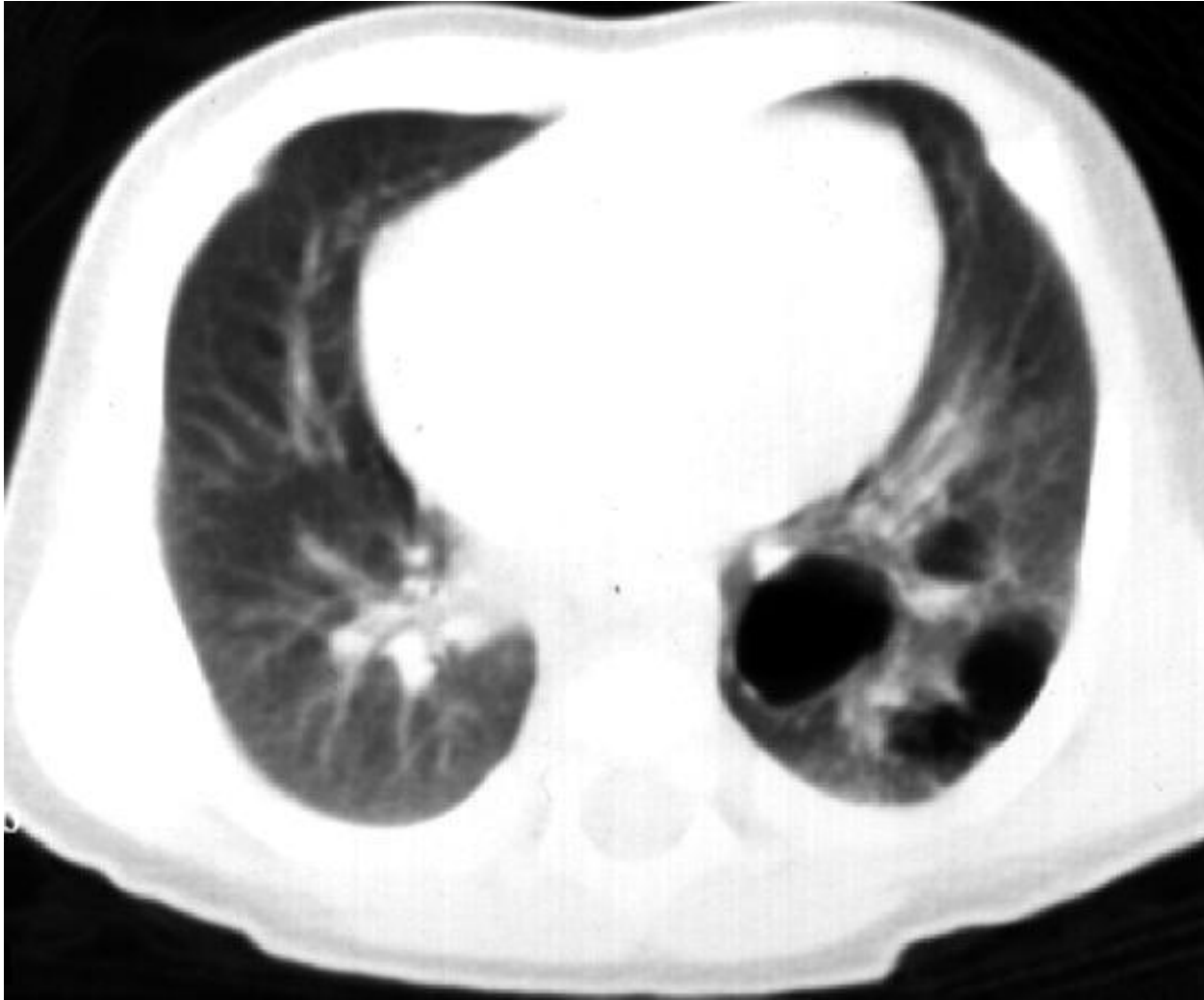

Konjenital Kistik Adenomatoid Malformasyon

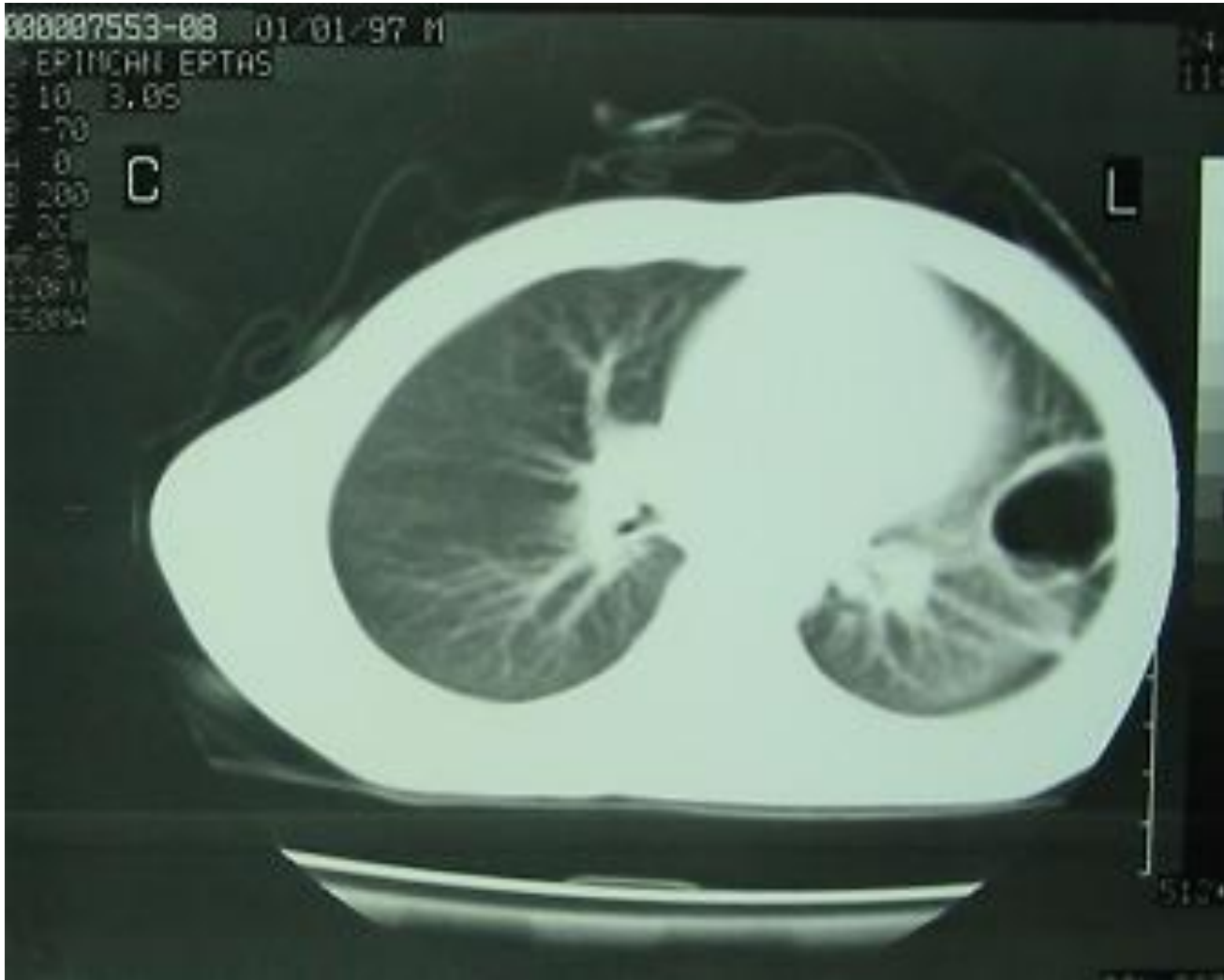




Kistik adenomatoid malformasyon

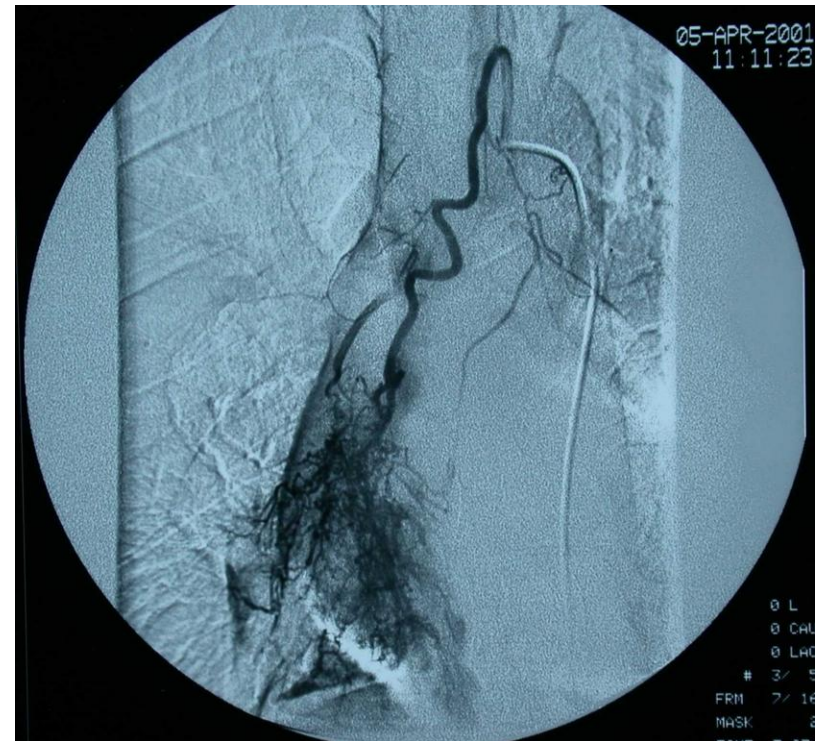
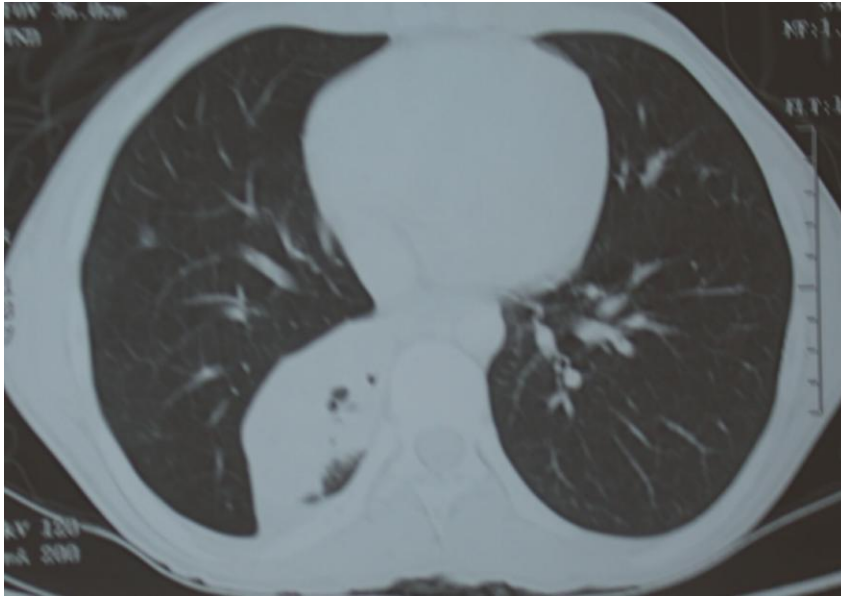

Kistik adenomatoid malformasyon

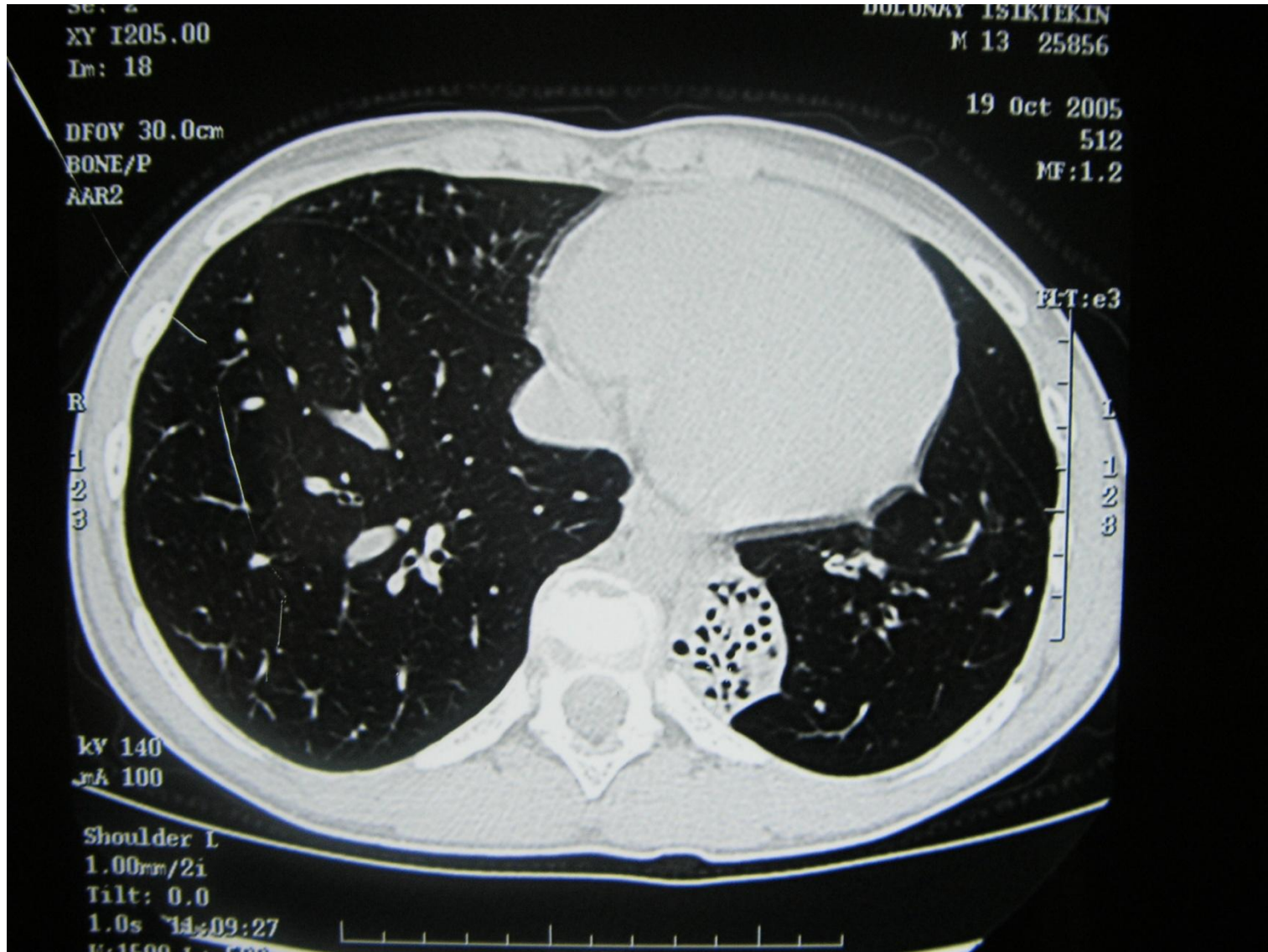


Konjenital bül opere

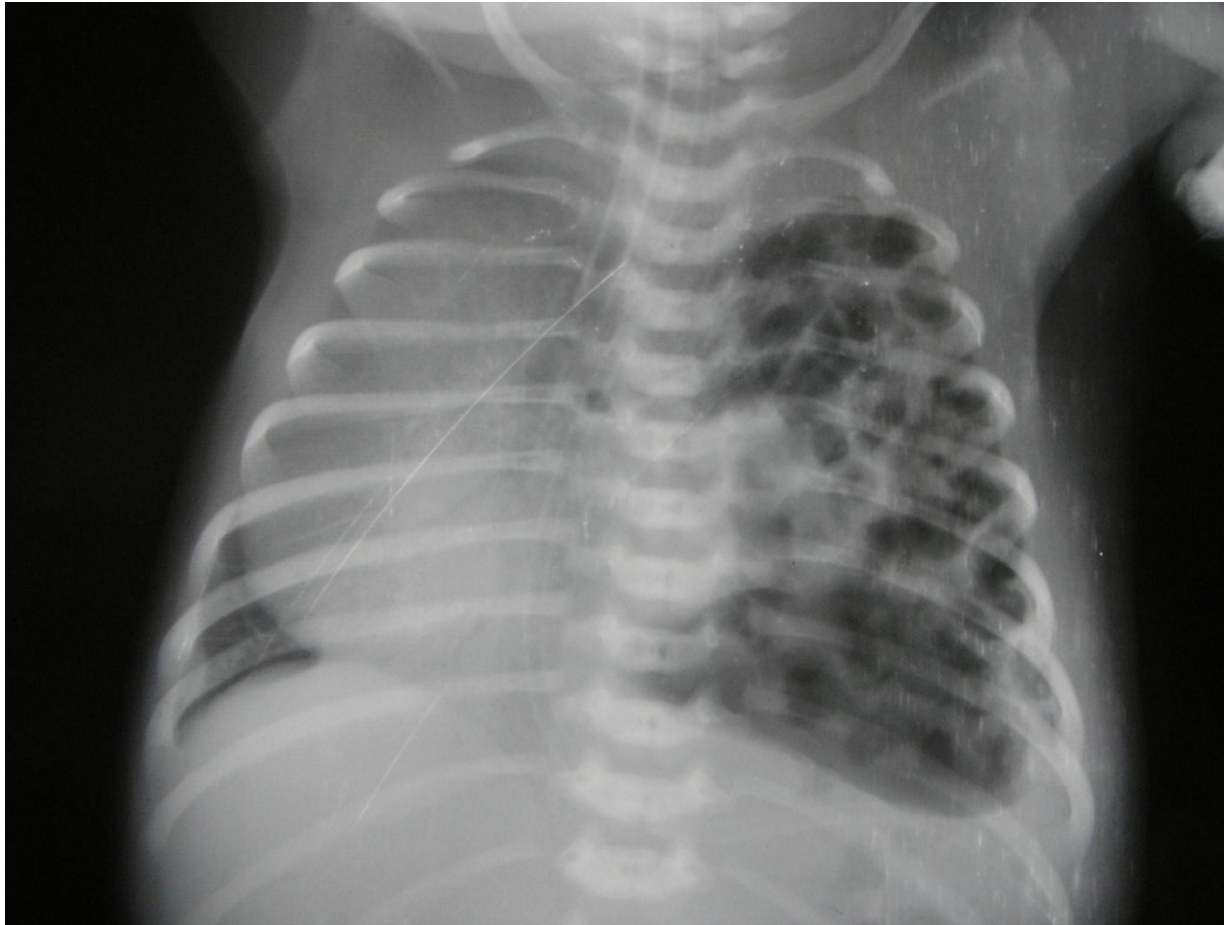
Pulmoner Sekestrasyon

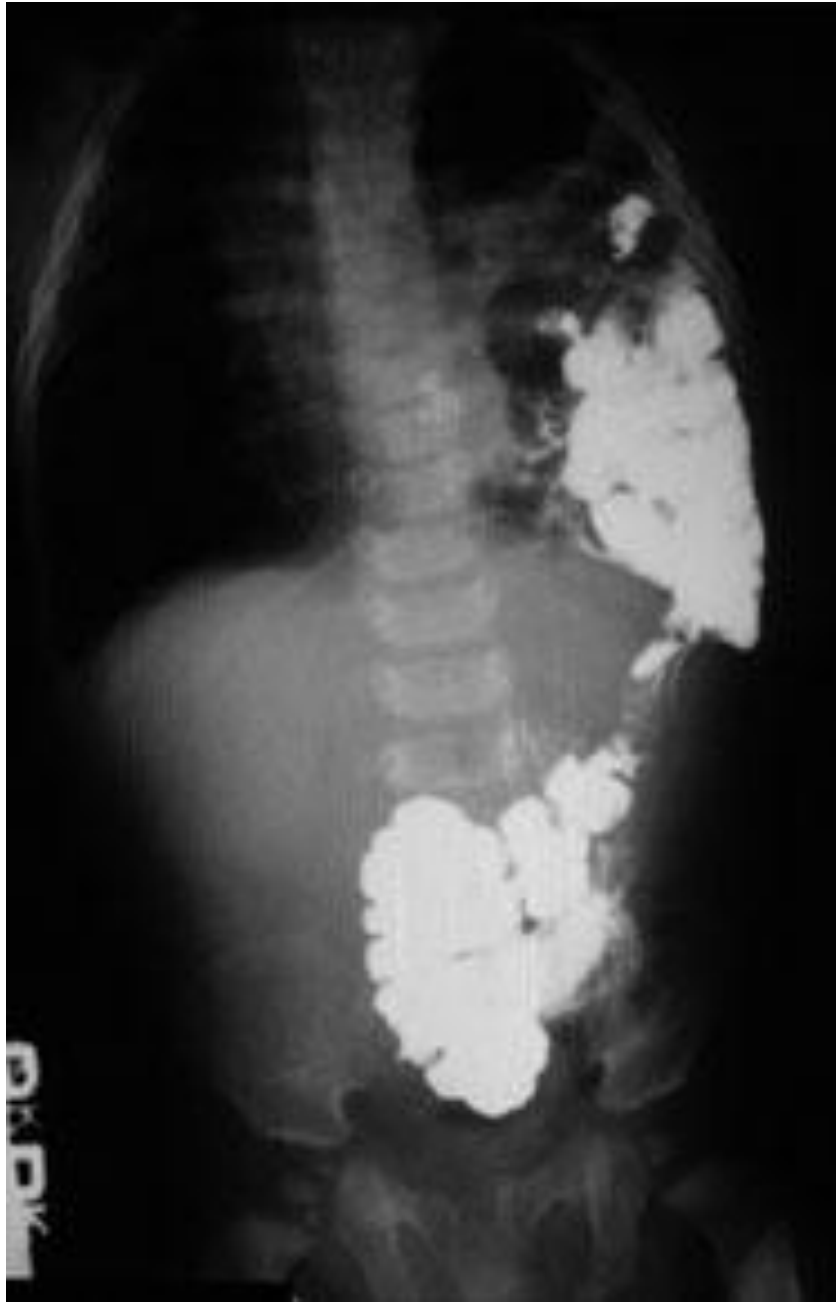

Sekestrasyon

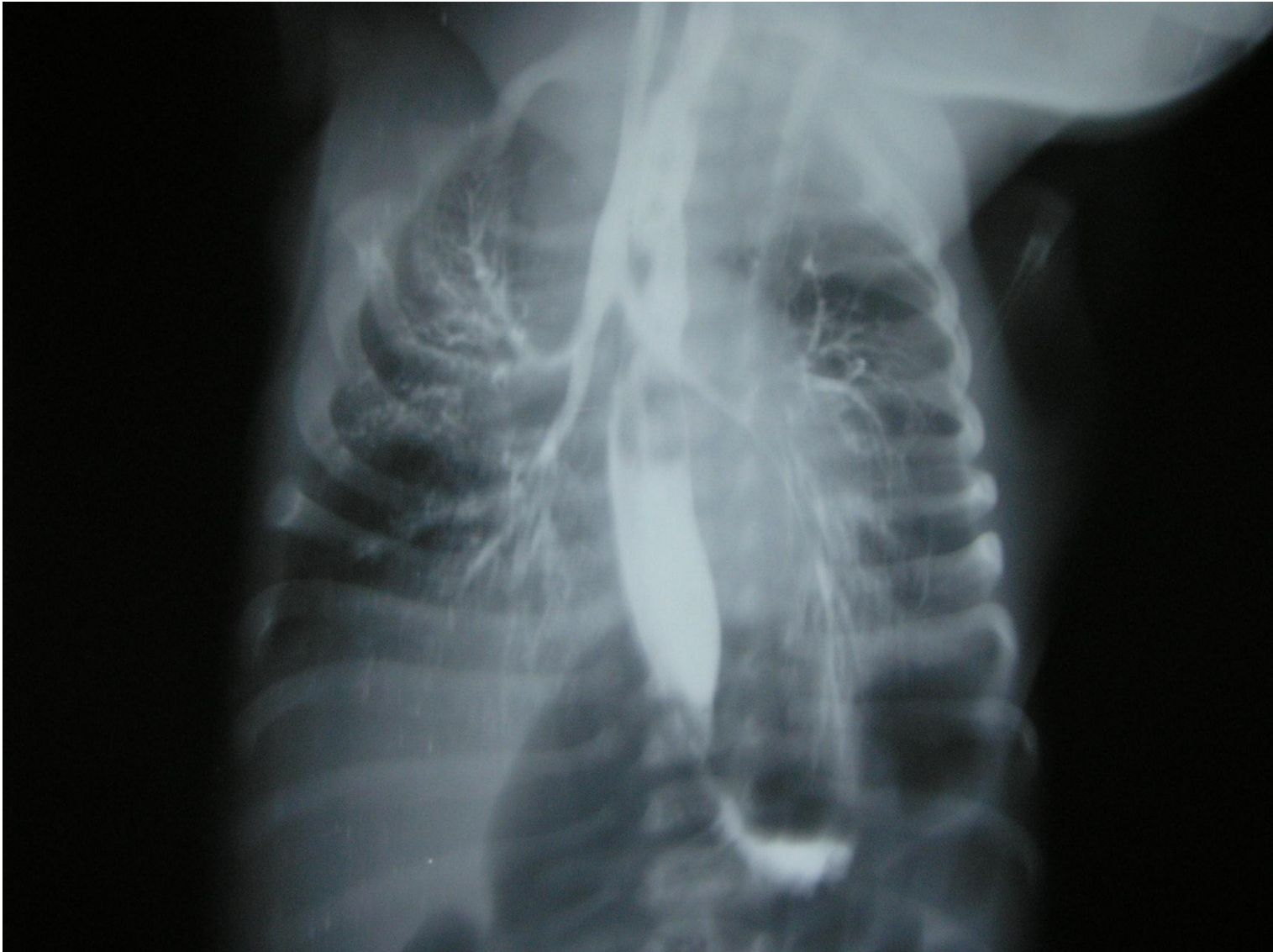


KONJENİTAL DİAFRAGMA HERNİSİ

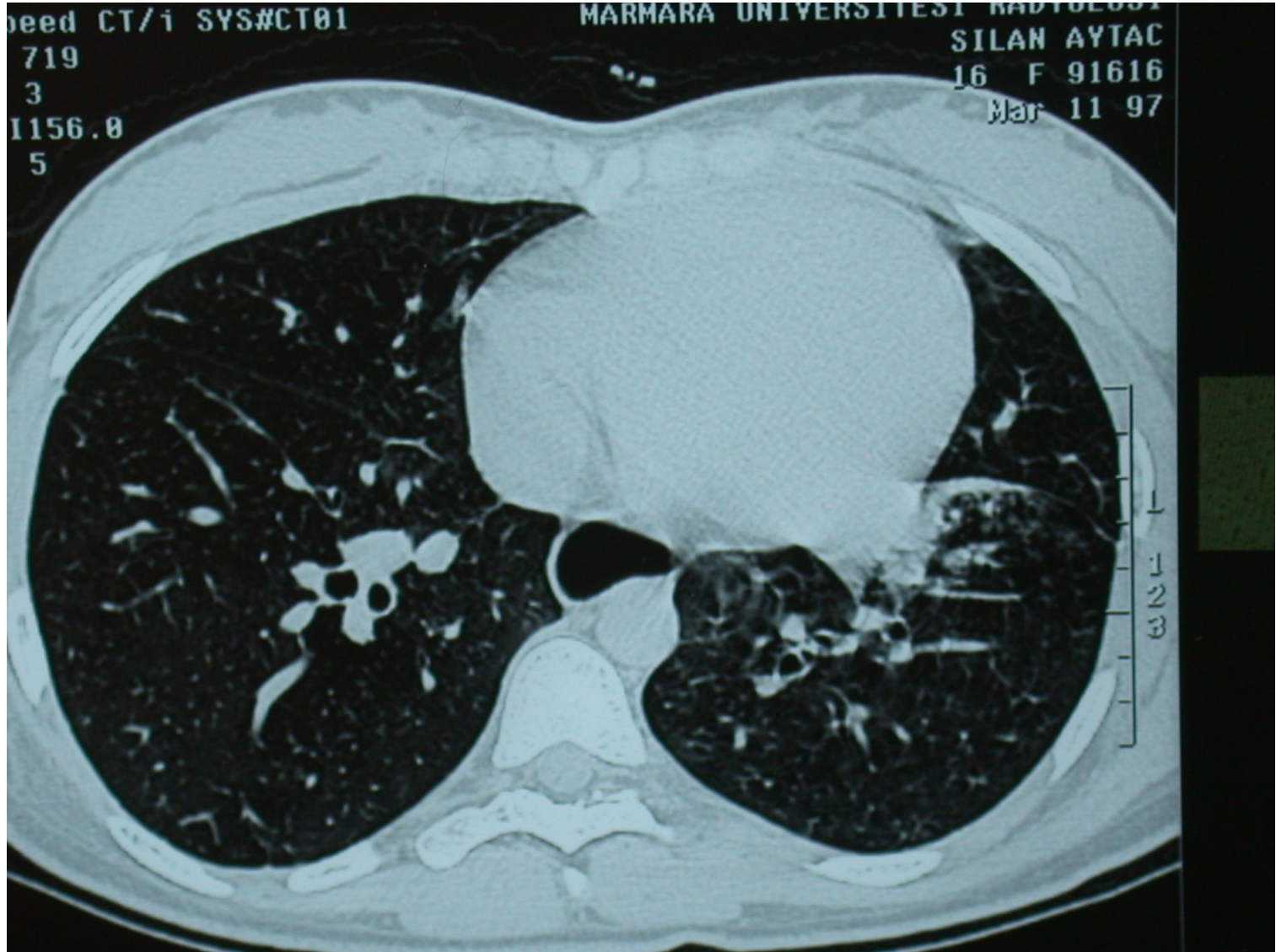


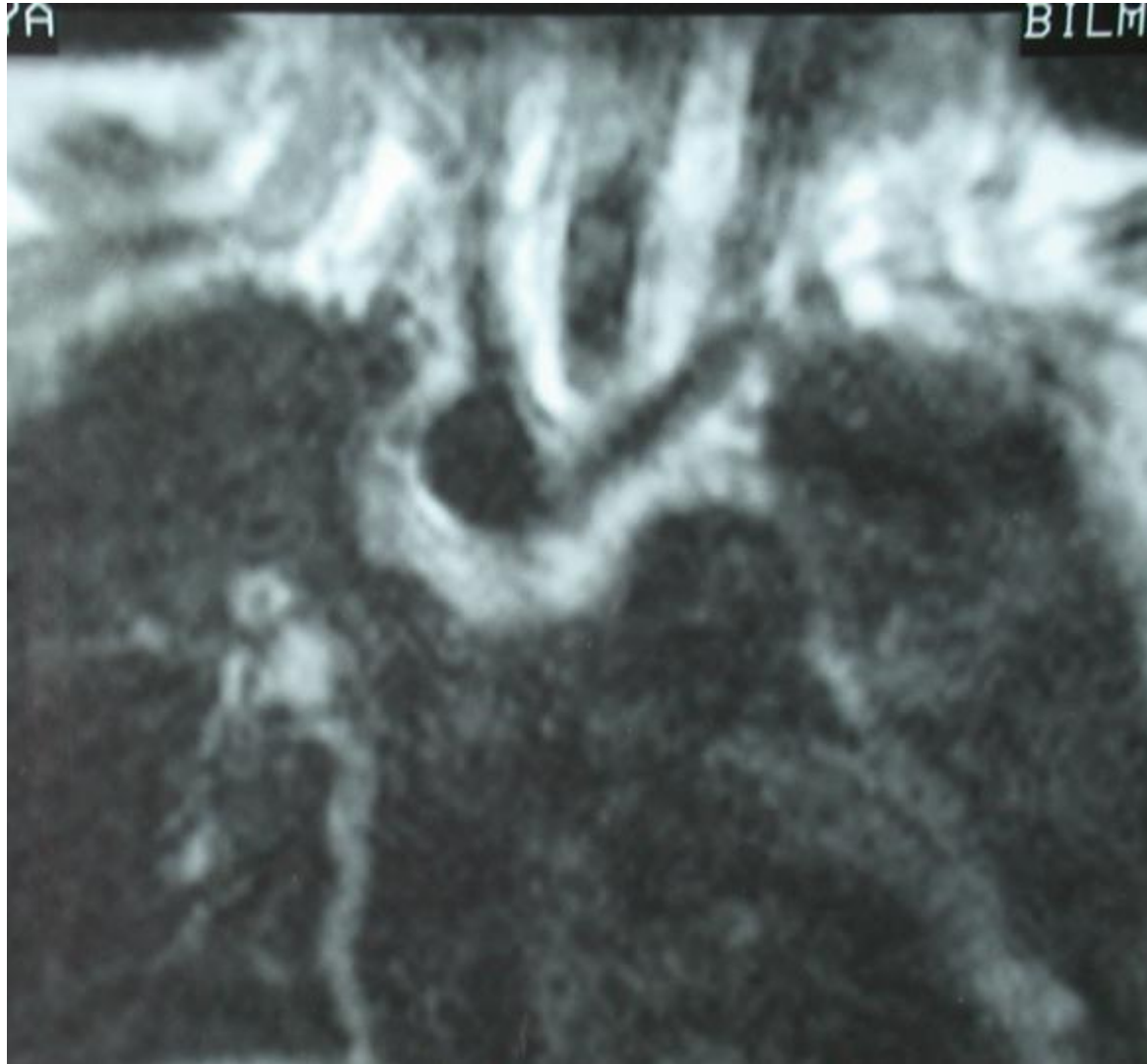


TRAKEO-ÖZOFAGIAL FİSTÜL/ÖMD



SA 20 yaşında hasta geçirilmiş ÖA+TEF op





Vasküler Ring

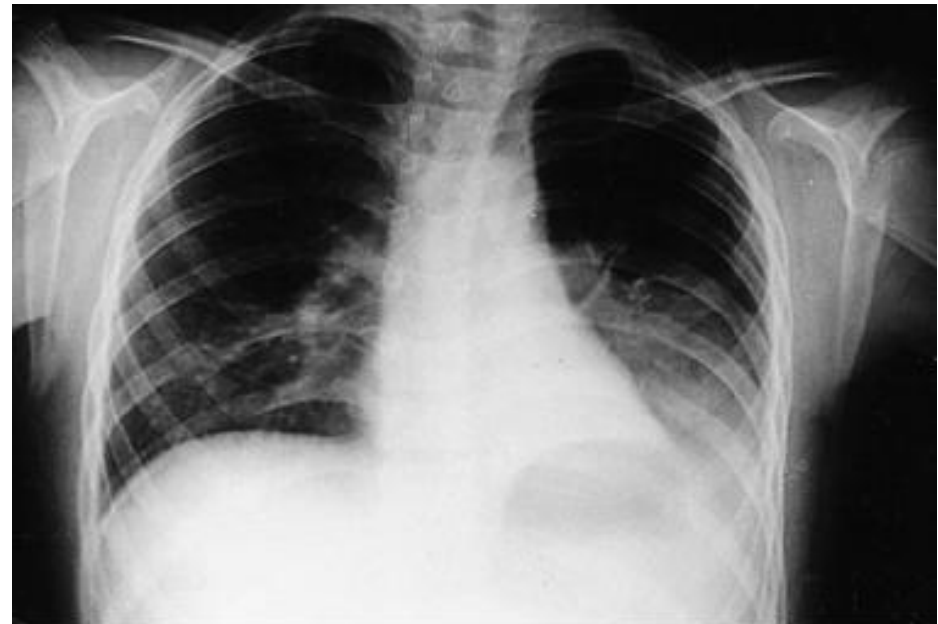
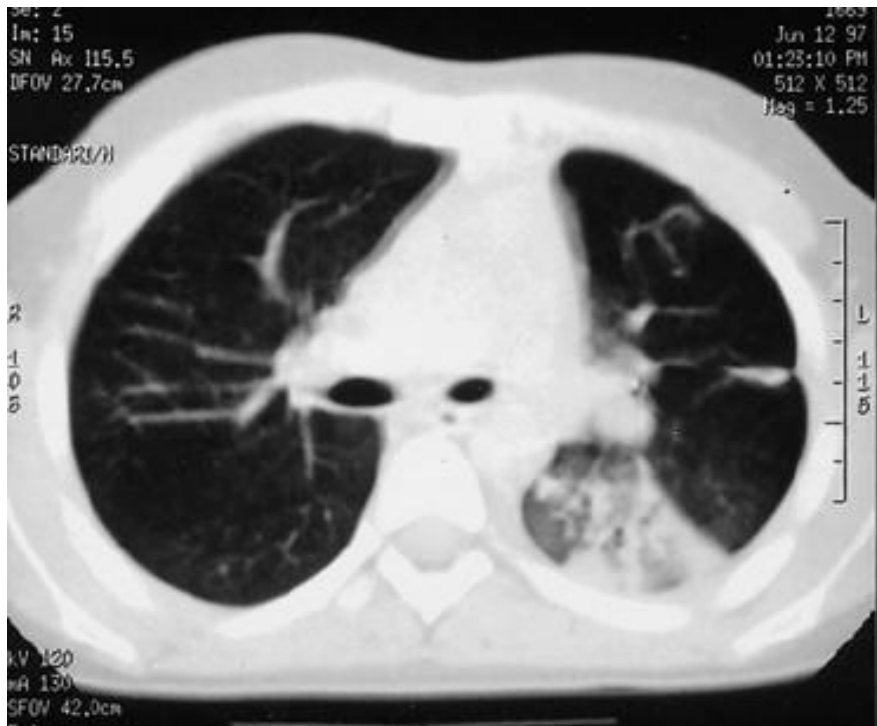
Sağ arkus aorta sol subklavian arter

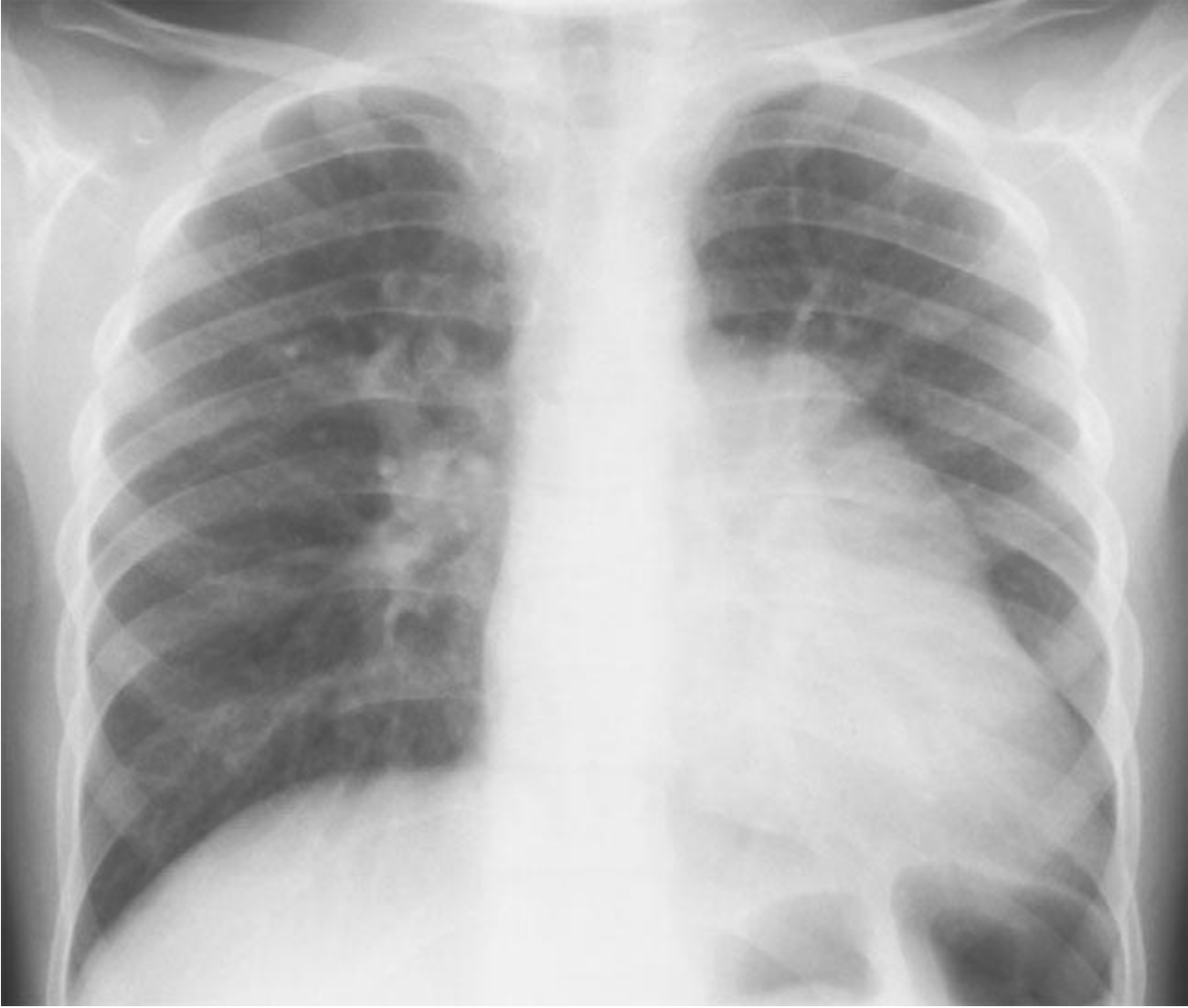Patient Report

Mucoepidermoid carcinoma of the bronchus: A rare entity in childhood

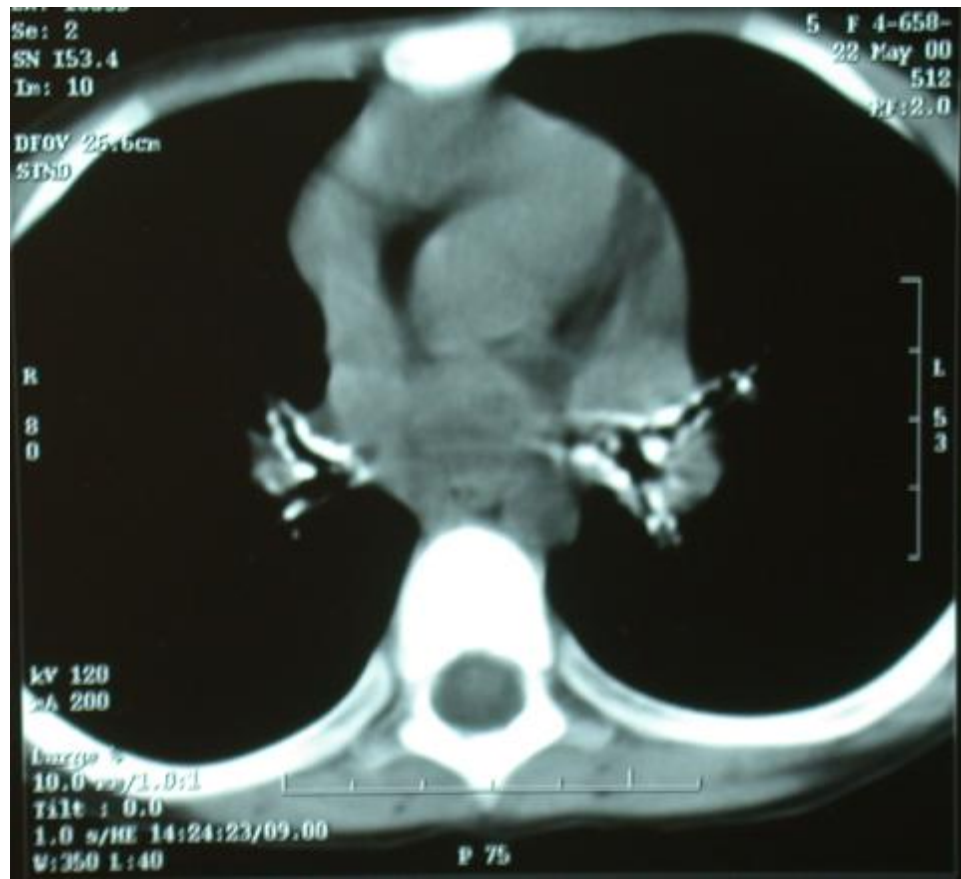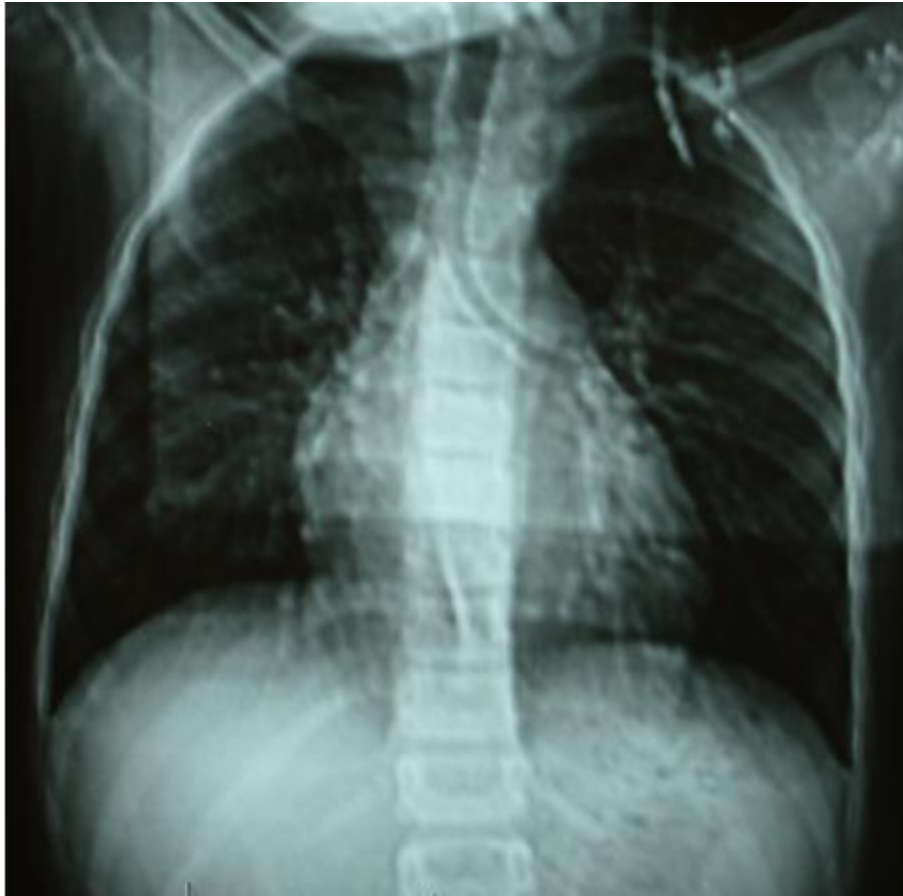ARIF KUT,¹ BULENT KARADAG,¹ FAZILET KARAKOC,¹ REFIKA ERSU,¹
BEDRETTIN YILDIZELI,² ESIN KOTILOGLU,³ MUSTAFA YUKSEL² AND ELIF DAGLI¹

Departments of ¹Pediatric Pulmonology, ²Thoracic Surgery and ³Pathology, Marmara University Hospital, Istanbul, Turkey





Perikardın parsiyel yokluđu



Trakeal kalsifikasyon